



Stadtspital Zürich



# Complex Arrhythmias

Stephan Andreas Müller-Burri  
Cardiology Triemli, Stadtspital Zürich  
25. November 2021




Disclosures: Fellowship and training support from Biotronik, Boston Scientific, Medtronic, Abbott/St. Jude Medical, and Biosense Webster. Speaker honoraria from Biosense Webster, Medtronic, Abbott/St. Jude Medical, AstraZeneca, Daiichi Sankyo, Biotronik, MicroPort, Novartis. Consultant for Biosense Webster, Medtronic, Abbott/St. Jude Medical, and Biotronik.

---


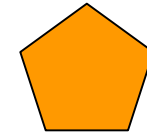

# Agenda

---


(1) Complex electrocardiograms



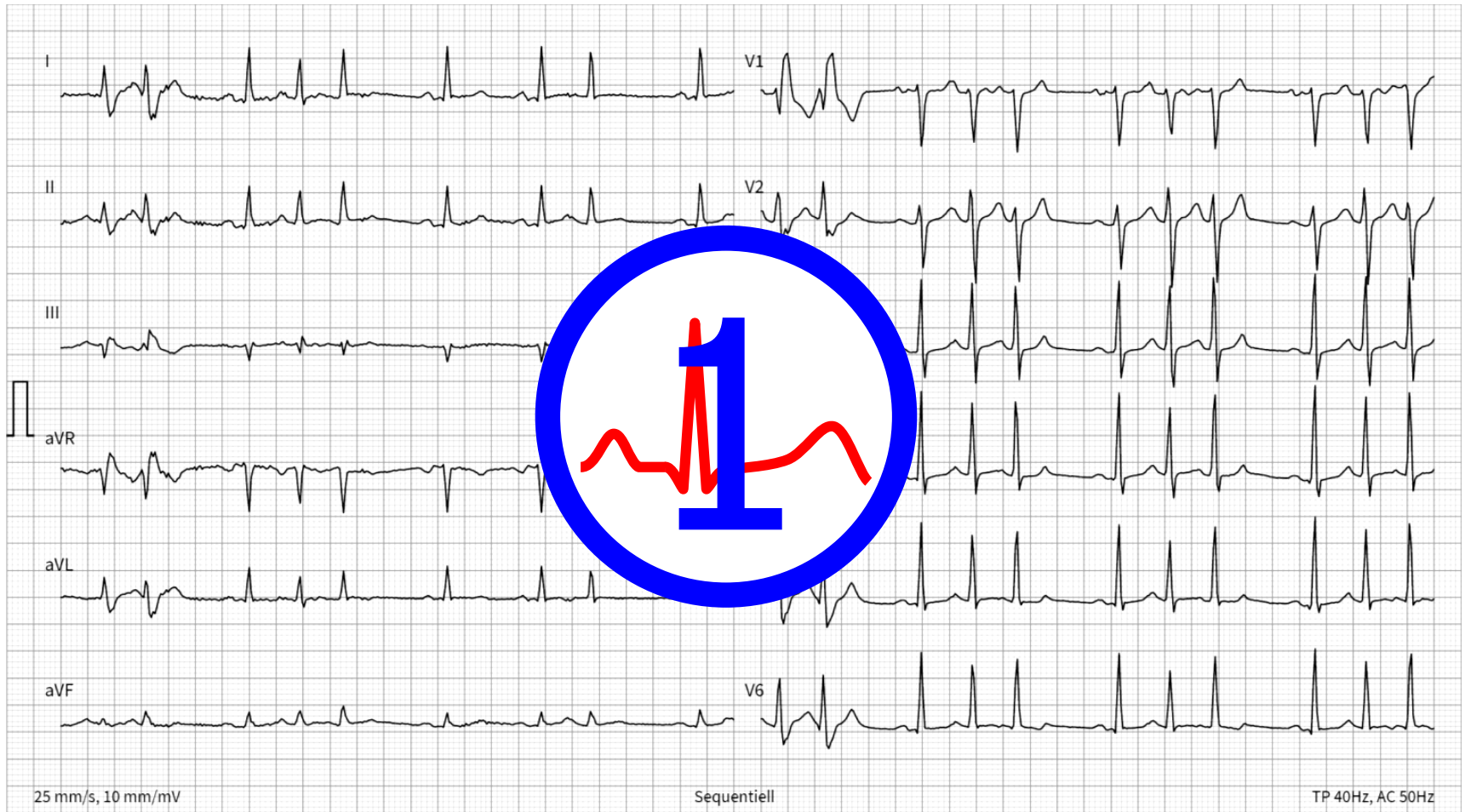
(2) Complex arrhythmia treatment




(3) Complex device situations



# Complex ECG





# Case 1: History

44-year-old patient with pericardial effusion and tachycardias

## Personal history

Multiple drug use

Autosomal dominant polycystic kidney disease

3/21 Start hemodialysis

5/21 Bilateral nephrectomy

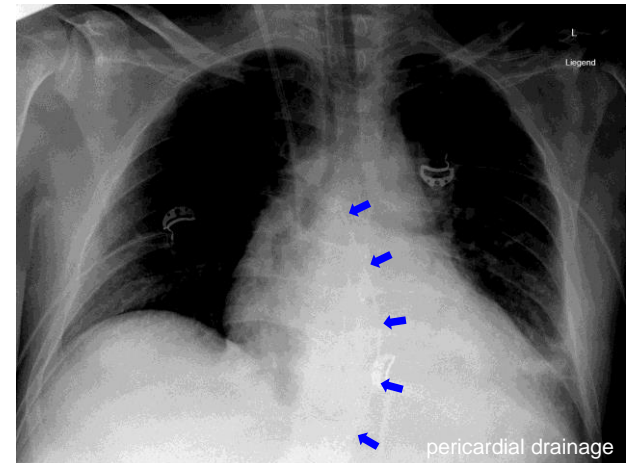
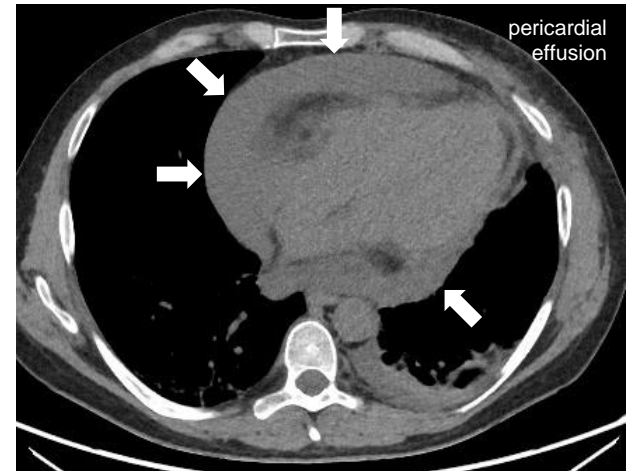
## Cardiac history


Chronic progressive pericardial effusion of unknown etiology

## Therapy

Surgery for subxyphoidal pericardial drainage

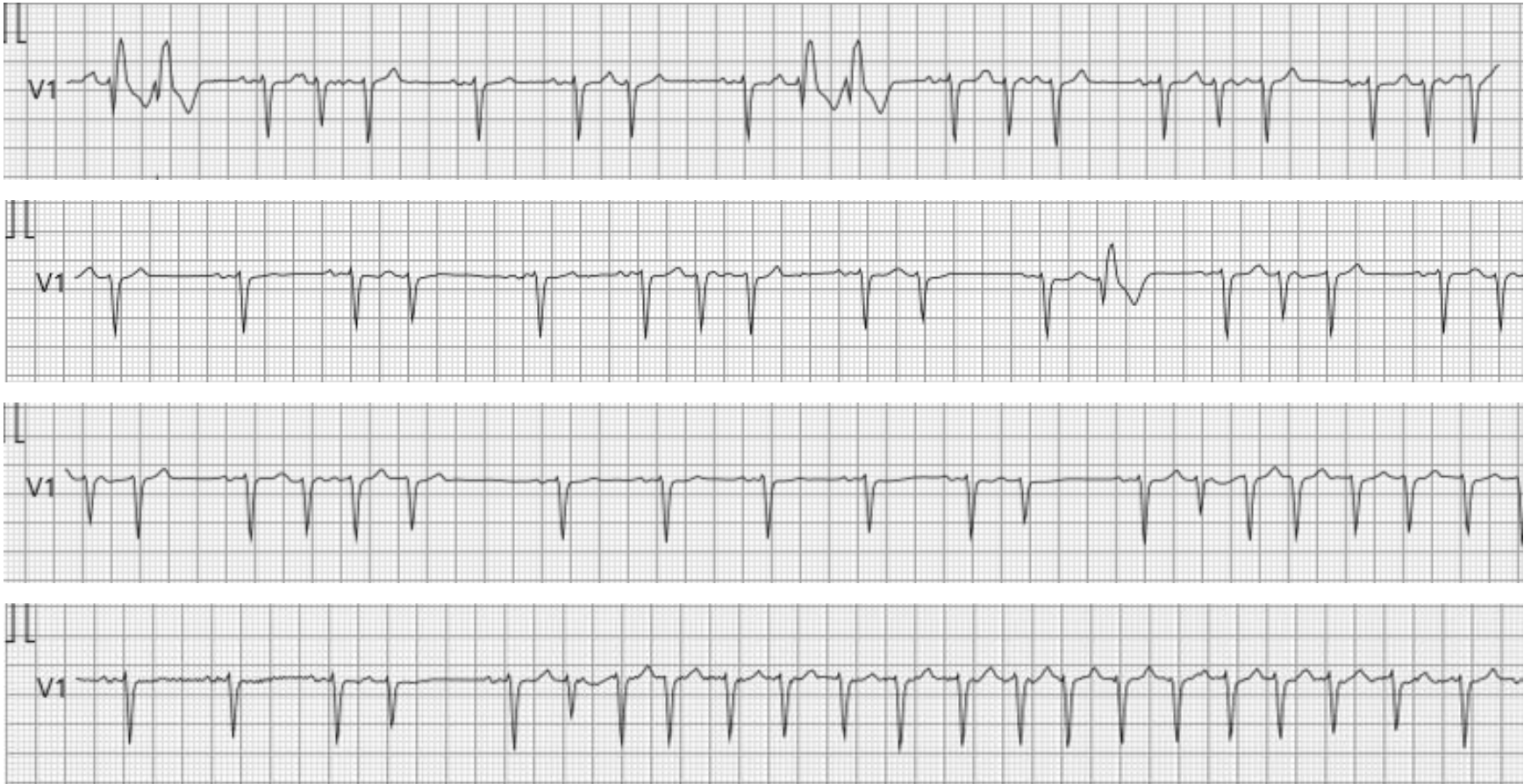
Transfer to ICU






# Case 1: ECG

## ECG monitoring



**ECG:** Repetitive wide and narrow QRS tachycardia triggered by painful deep inspiration.

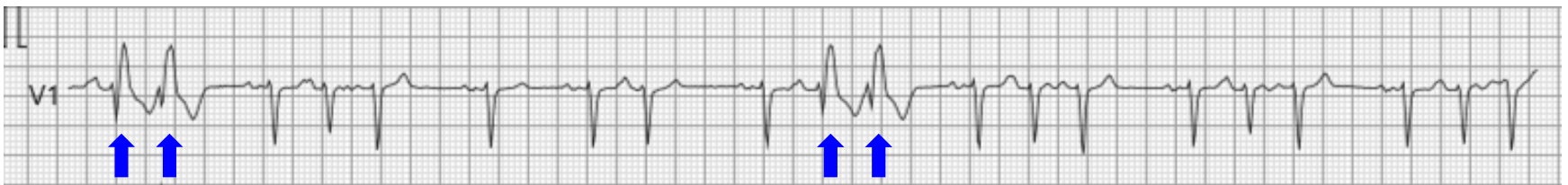

# Case 1: Question

44-year-old patient with pericardial effusion and tachycardias

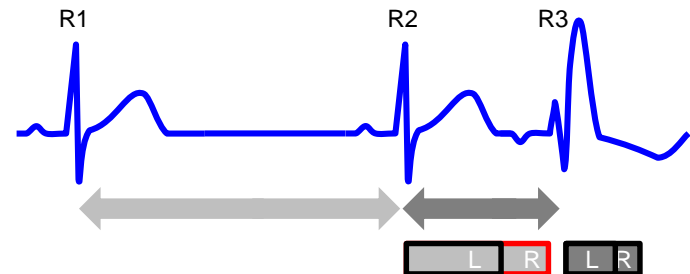
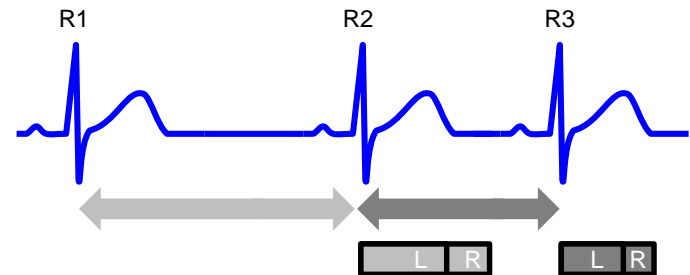
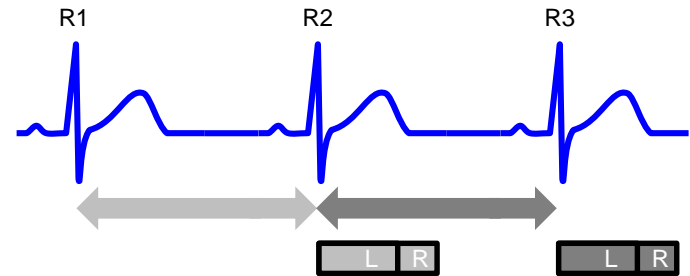
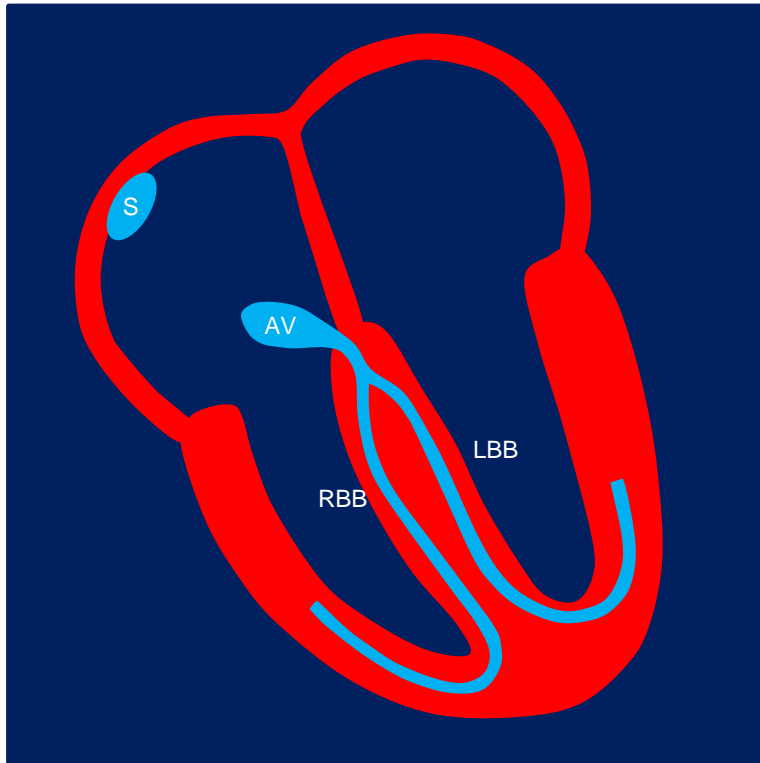How would you treat this patient? (more than one correct answer)

- (A)  $\beta$ -blocker
- (B) Amiodarone
- (C) Anticoagulation
- (D) Coronary angiography
- (E) Removal of the pericardial drainage




**ECG:** Repetitive wide and narrow QRS tachycardia triggered by painful deep inspiration.

# Phase 3 block / Ashman phenomenon



The length of R1R2 interval determines the duration of the effective refractory period (ERP) of the His-Purkinje system (HPS). The longer the RR interval, the longer the next ERP of the bundle branches (LBB < RBB).

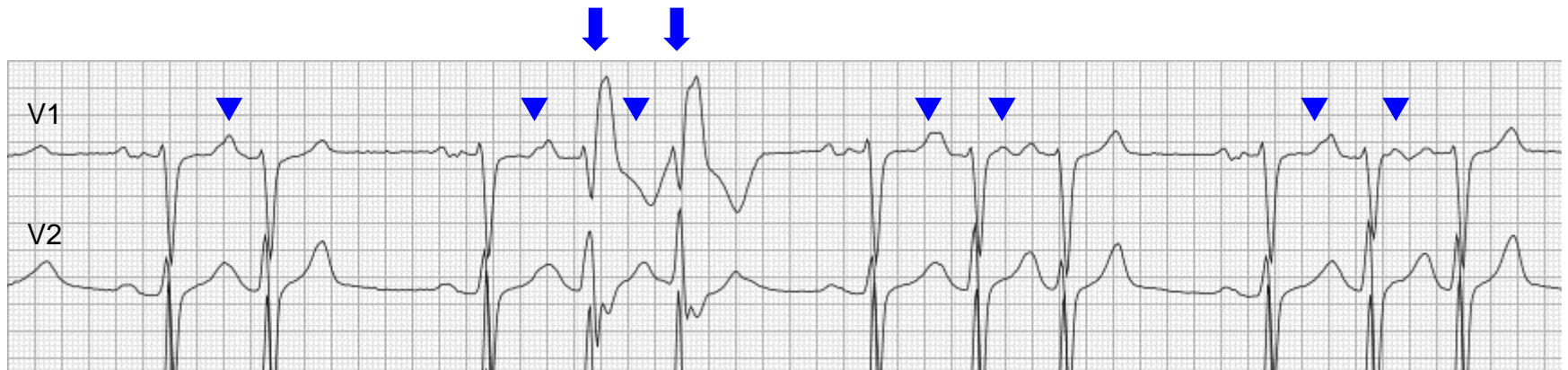
An early PAC may encounter a partially refractory HPS with an open LBB and a still blocked RBB.



# Case 1: Diagnosis and therapy

## Diagnosis

Repetitive non-sustained atrial tachycardias due to mechanical irritation with intermittent aberrant AV conduction (RBBB, Ashman phenomenon).




**ECG:** Repetitive atrial extrasystoles (arrow heads) with intermittent aberrant conduction (RBBB, arrows)

## Therapy

Removal of the pericardial drainage.





# Case 2: History

76-year-old patient with paroxysmal AV block III

## Personal history

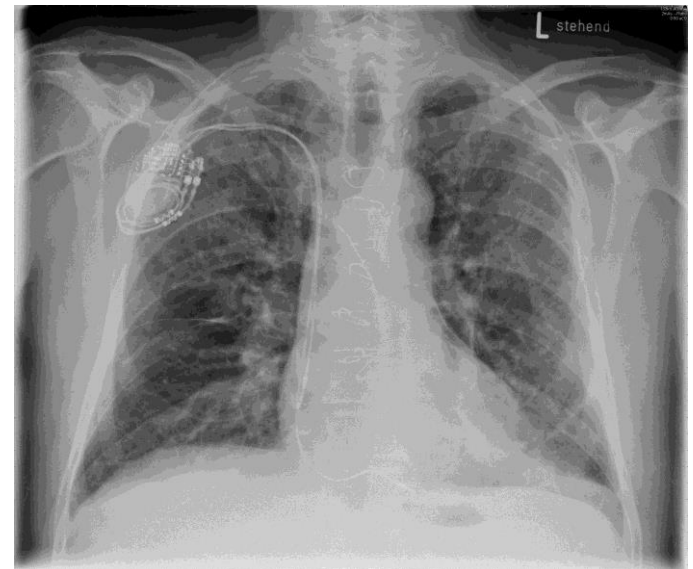
- Arterial hypertension
- Obesity and sleep apnea syndrome
- Coxarthrosis, hip replacement


## Current admission

Repetitive paroxysmal AV block III during postoperative telemetry, pauses up to 8 s

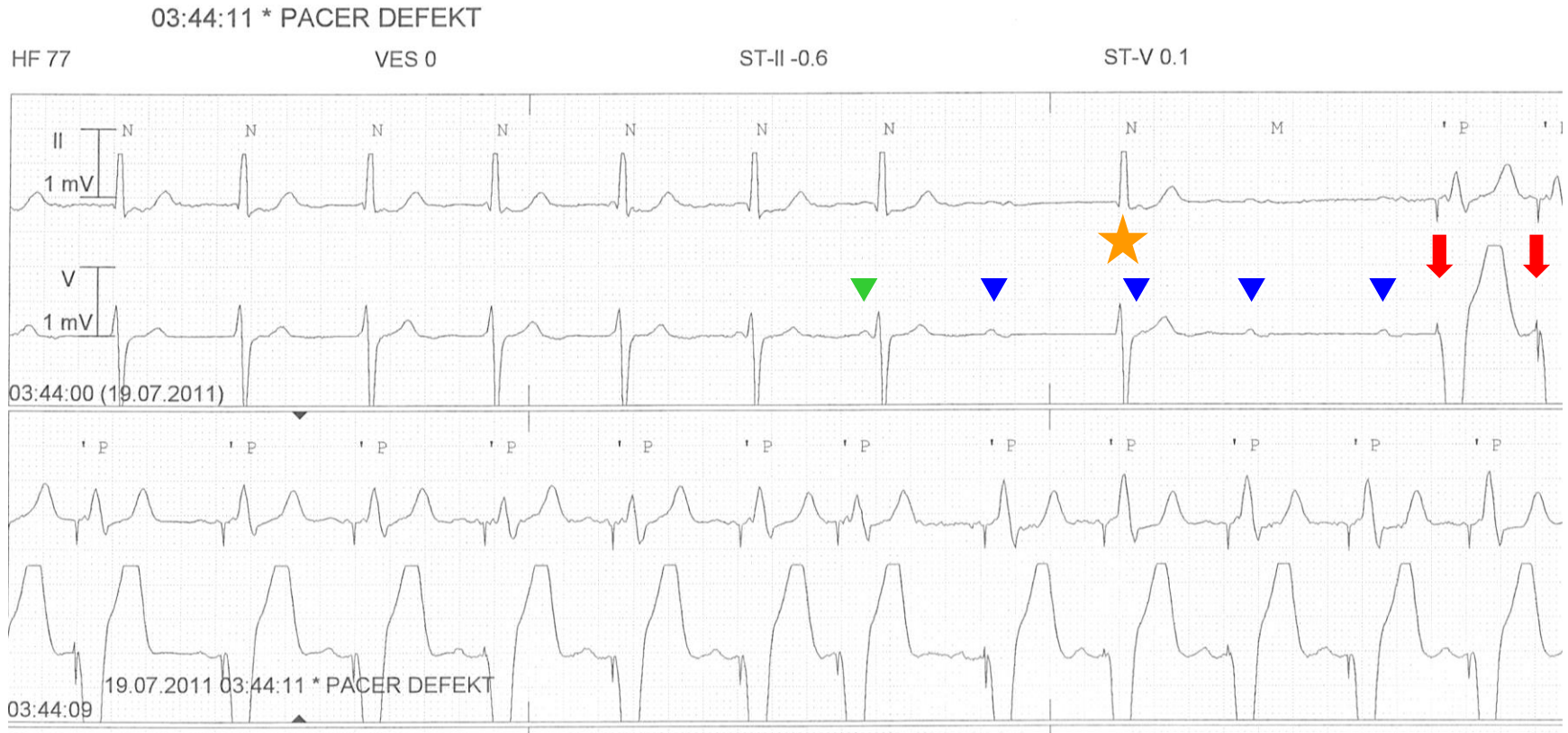
## Therapy

Implantation of a dual chamber pacemaker  
Programming: out of the box






# Case 2: Telemetry



**Telemetry alert:** Pacer Defect! SR. Paroxysmal AV-block with junctional escape rhythm (asterisk) followed by A triggered RV pacing.

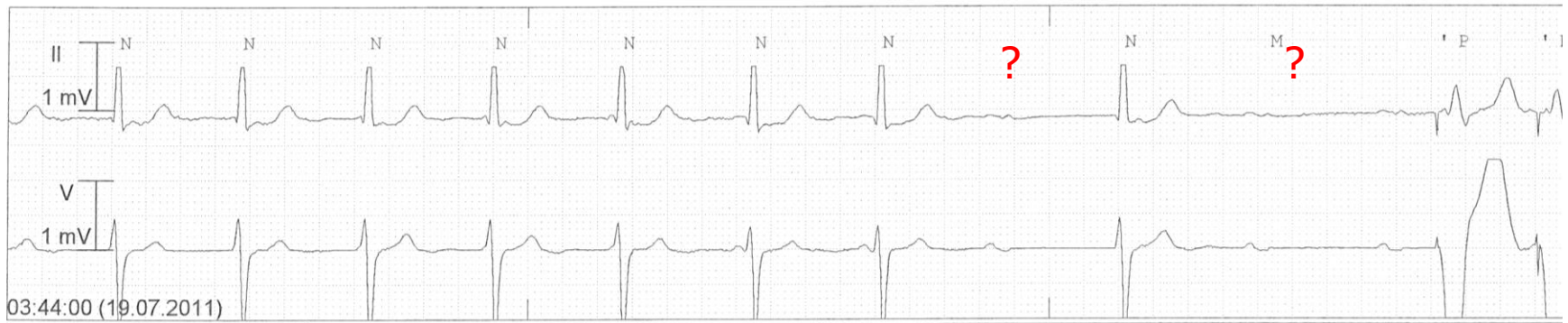



## Case 2: Question

76-year-old patient with AV block III and permanent pace maker

How would you treat this patient? (more than one correct answer)

- (A) Repeat chest X-ray: verify lead position
- (B) Call the cardiologist: check and reprogram the PM
- (C) Call the surgeon: immediate PM revision
- (D) Ignore the alert and fix the problem next morning
- (E) Ignore the alert. Normal function of a "modern" PM

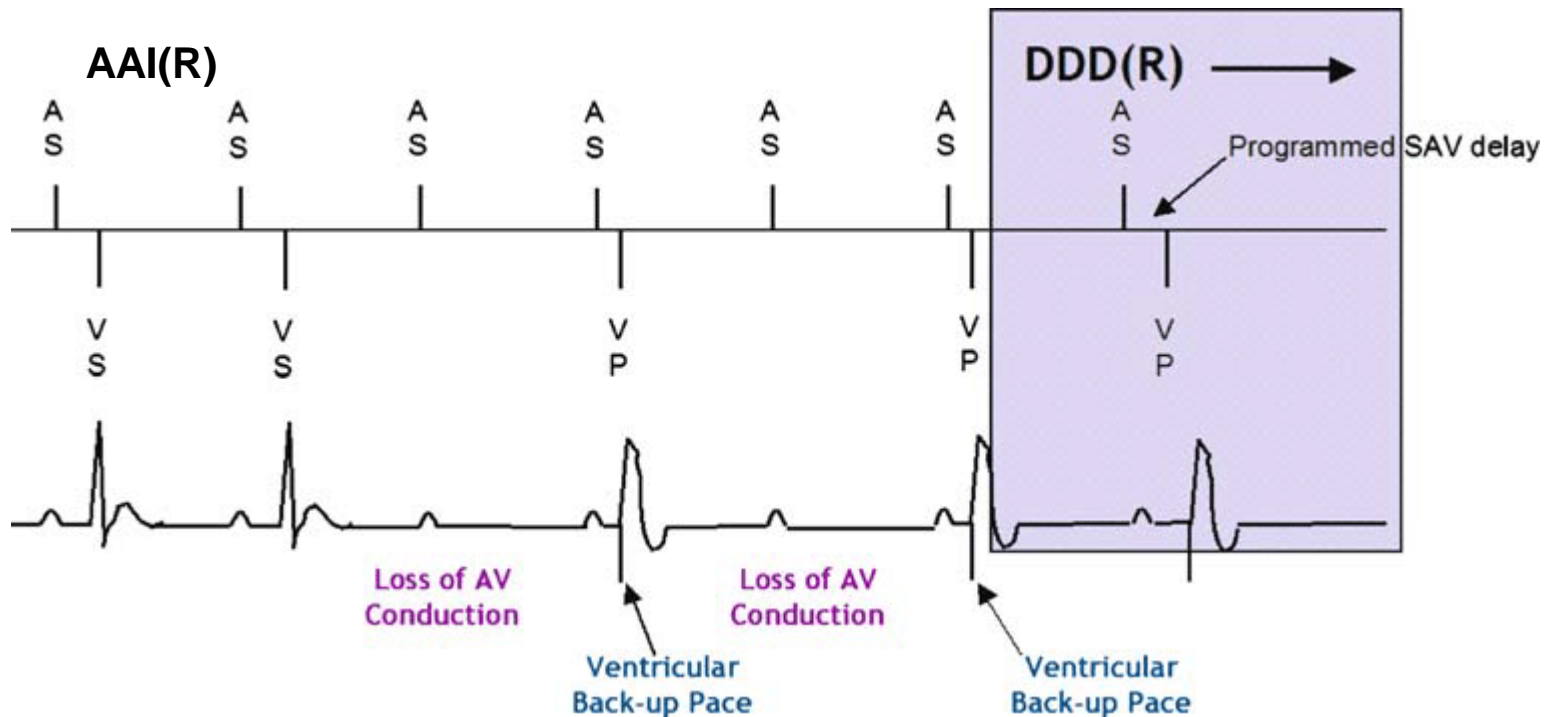





# Case 2: Diagnosis and therapy

## Diagnosis

Standard Medtronic AAI-DDD mode. Aim: Minimize ventricular pacing.(2)



**Therapy:** no specific action needed.



---

# Case 3: History

---

76-year-old lady living in a nursing home with fast atrial fibrillation.

## Personal history


- Arterial hypertension
- Diabetes mellitus type 2
- Carotid and peripheral atherosclerosis with vascular bypass surgery
- Chronic kidney disease, Creatinine 315  $\mu\text{mol/l}$ , CrCl 13 ml/min
- Permanent atrial fibrillation with fast ventricular response

## Drugs before admission

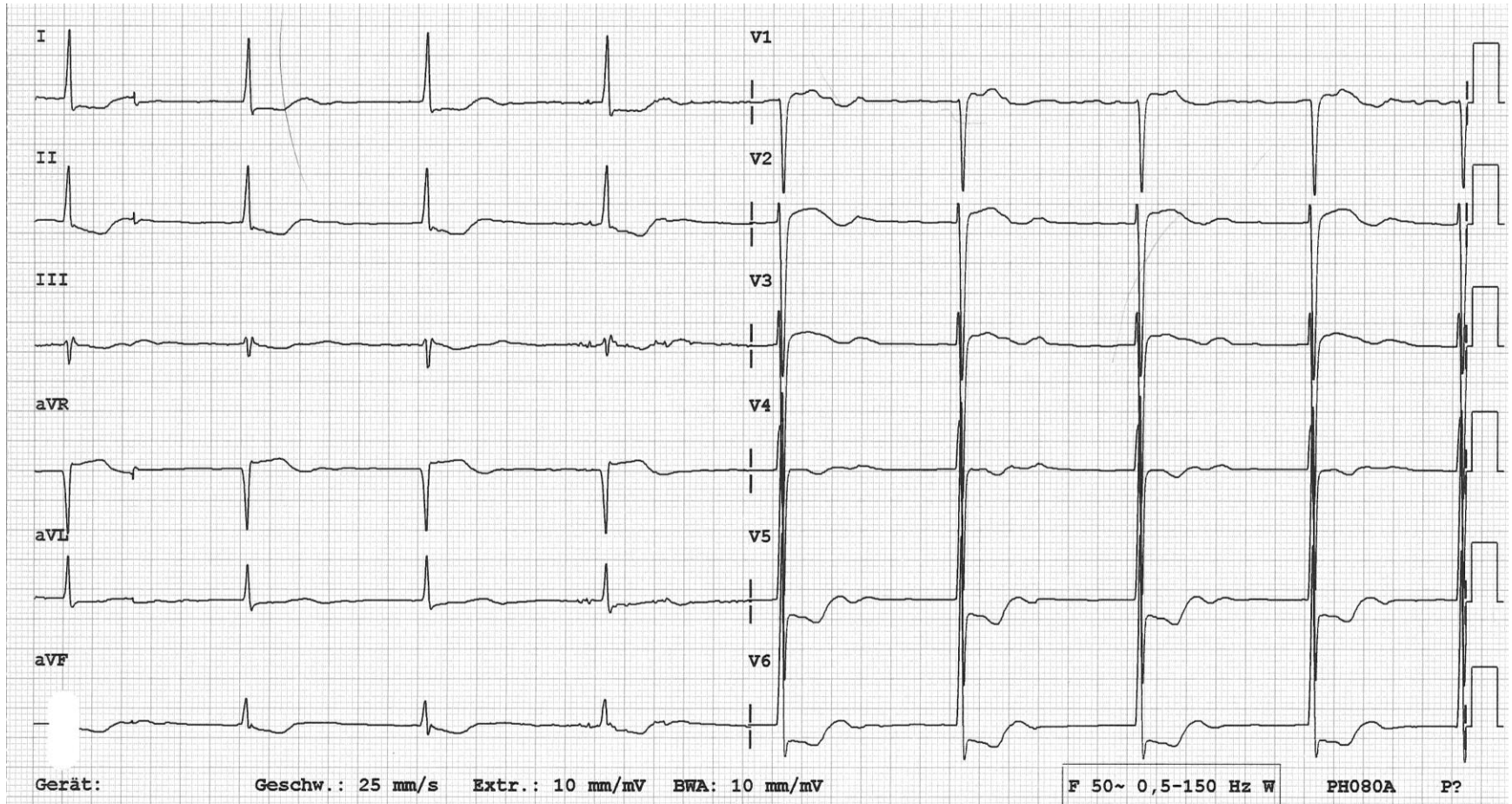
Rivaroxaban 20 mg/d, ramipril 5 mg/d, torasemid 20 mg/d, bisoprolol 10 mg/d, diltiazem 180 mg/d, digoxin 0.25 mg/d, statin, oral antidiabetic drugs, insulin.

## Current admission

Admission because abdominal pain, nausea and vomiting.




# Case 3: ECG



**ECG:** Slow regular narrow QRS rhythm. HR 50 bpm.

**Laboratory values:** Hb 9.8 g/dl, Lc 8.2 G/l, Tc 193 G/l, CRP 56 mg/l, Na 133 mmol/l, K 3.99 mmol/l, Crea 233 µmol/l.

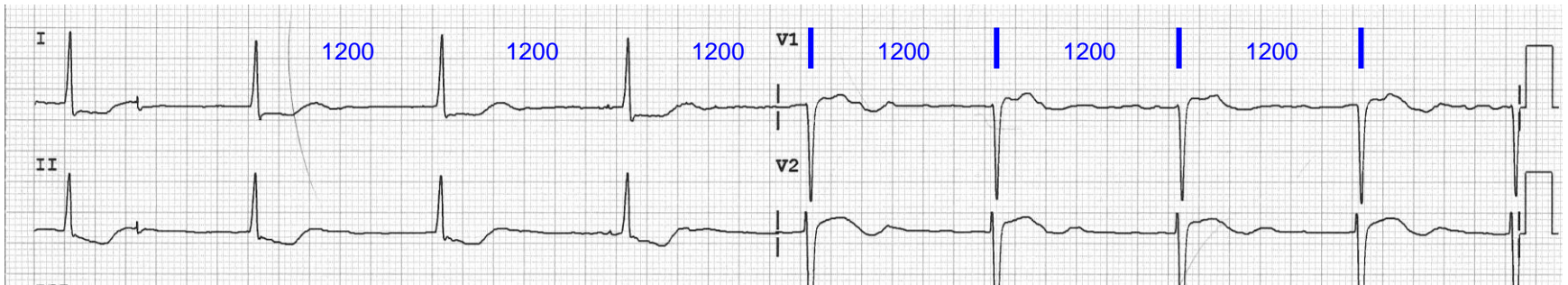


# Case 3: Question


76-year-old lady living in a nursing home with fast atrial fibrillation.

How would you treat this patient? (more than one correct answer)

- (A) Laboratory values
- (B) Temporary pacemaker
- (C) Coronary angiography
- (D) Hemodialysis
- (E) Digoxin antibodies (Fab)



**ECG:** AF with complete AV block and junctional escape rhythm with a narrow QRS (HR 50 bpm).



# Case 3: Diagnosis and therapy

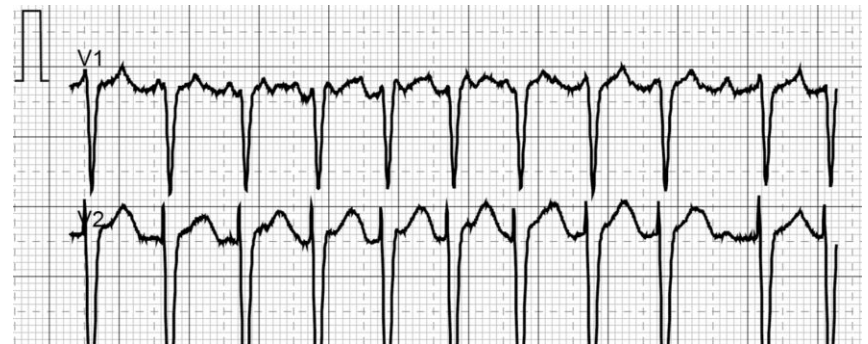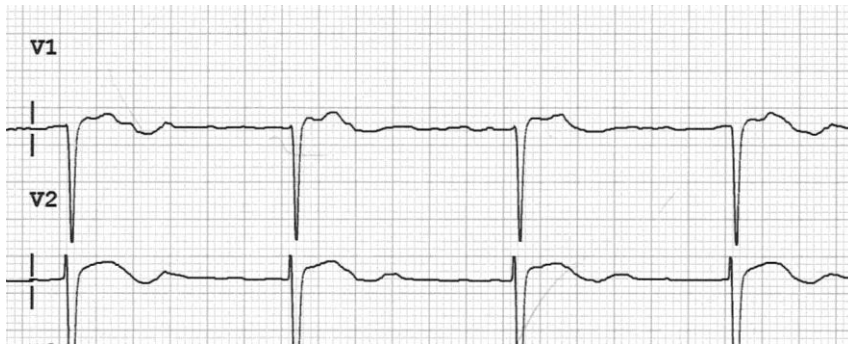## Diagnosis

### 1. Digoxin intoxication (cardiac glycoside poisoning)

- Digoxin 7.8 nmol/l
- Permanent AF, complete AV block and junctional escape rhythm

## Therapy

- Hemodynamic monitoring
- Antidote therapy (Fab antibodies)
- New adjustment of rate control drugs



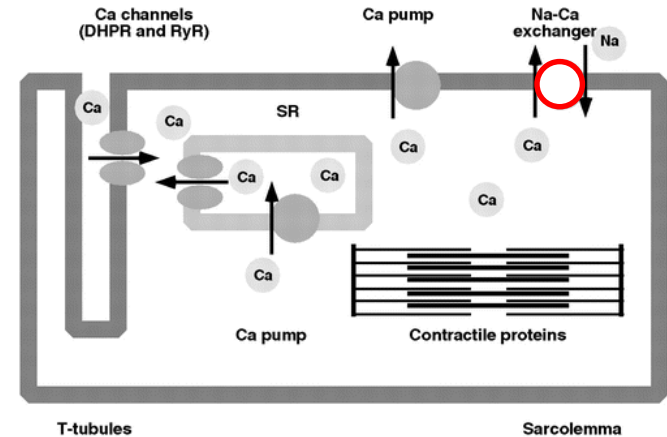
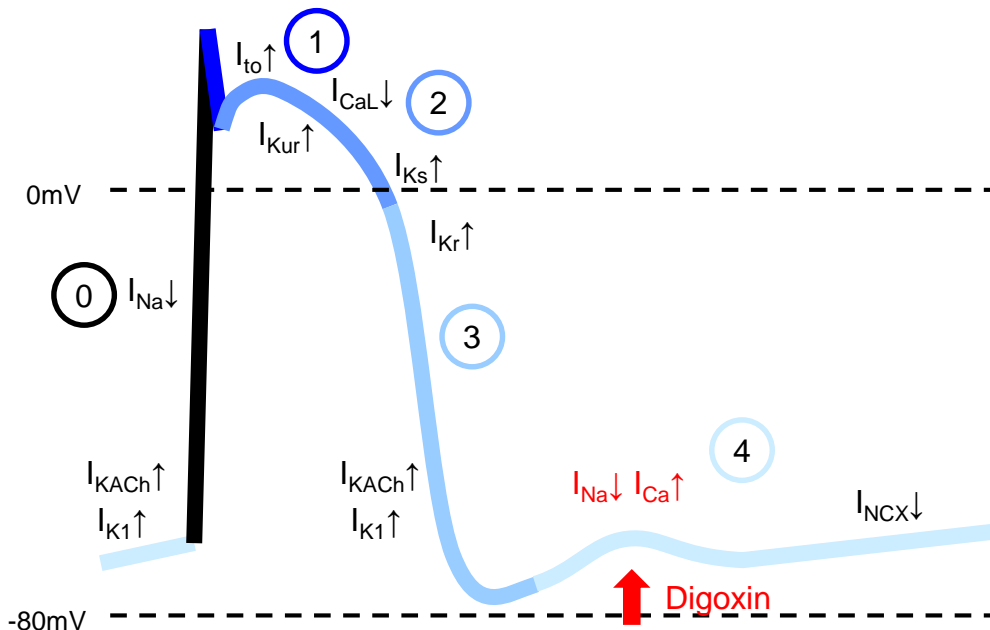


# Digoxin toxicity

## Actions of digoxin

- Inhibition of the  $\text{Na}^+/\text{K}^+$ -ATPase  $\rightarrow$  intracellular  $[\text{Na}^+] \uparrow \rightarrow$  intracellular  $[\text{Ca}^{2+}] \uparrow \rightarrow$  Inotropy  $\uparrow$
- Increase in vagal tone  $\rightarrow$  slowing of the vHR in AF

## Mechanism of digitalis toxicity



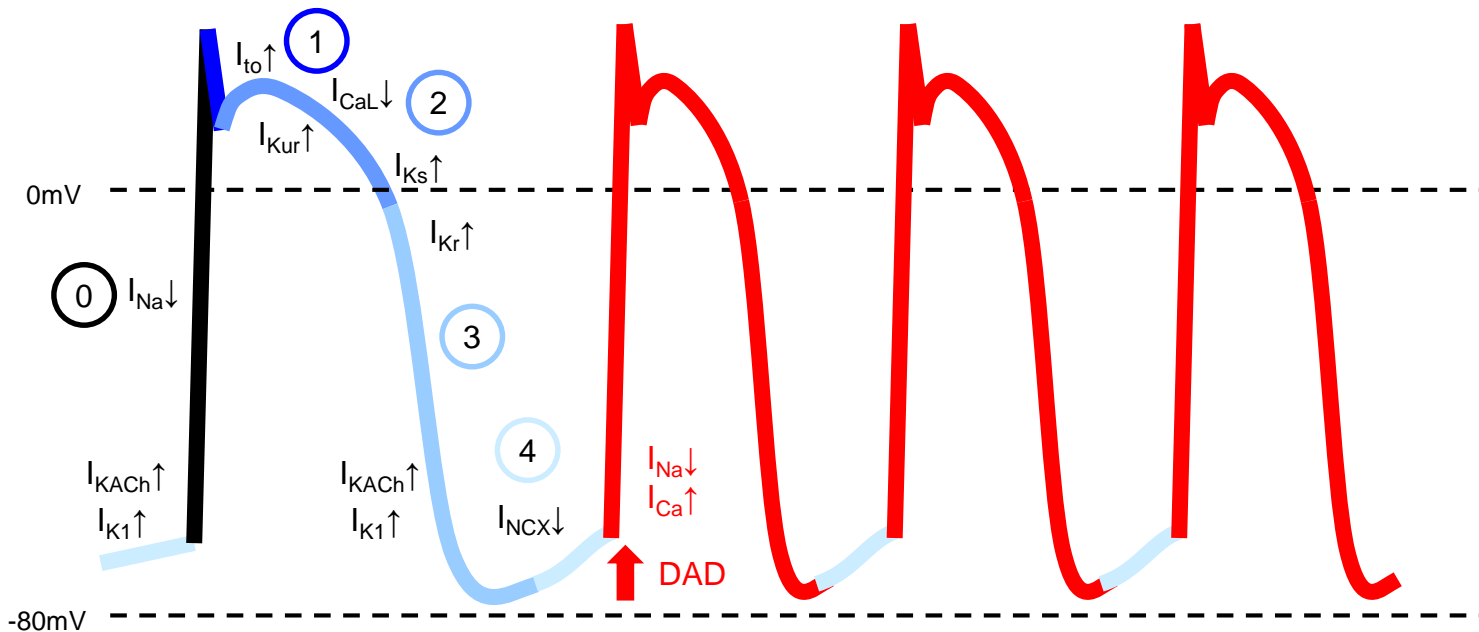
Digoxin induced intracellular  $\text{Ca}^{2+}$  overload promotes the increased activity of the  $\text{Na}^+/\text{Ca}^{2+}$  exchanger in Phase 4  $\rightarrow$  delayed after depolarization (DAD).

# Digoxin toxicity

## Actions of digoxin

- Inhibition of the  $\text{Na}^+/\text{K}^+$ -ATPase  $\rightarrow$  intracellular  $[\text{Na}^+] \uparrow \rightarrow$  intracellular  $[\text{Ca}^{2+}] \uparrow \rightarrow$  Inotropy  $\uparrow$
- Increase in vagal tone  $\rightarrow$  slowing of the vHR in AF

## Mechanism of digitalis toxicity



---

# Digoxin toxicity

---

## Plasma levels

Digoxin  $\geq$  1.7-2.0 nmol/l (no correlation with toxicity)

## Risk factors for clinical manifestation

- Hypokalemia, especially as a trigger for cardiac arrhythmias
- Hypomagnesemia
- Hypercalcemia
- Myocardial ischemia

## Symptoms

**Gastrointestinal:** anorexia, nausea, vomiting, and abdominal pain

**Neurological:** Changes in mental status as lethargy, fatigue, delirium, confusion, disorientation, and weakness.

**Visual changes:** chromatopsia, diplopia, photophobia, decreased visual acuity, photopsia, scotomas, or blindness

# Digoxin toxicity: cardiac arrhythmias

<b>Level</b>	<b>Bradyarrhythmias</b>	<b>Tachyarrhythmias</b>
Sinus node	<ul style="list-style-type: none"><li>• Sinus bradycardia</li><li>• SA block</li></ul>	<ul style="list-style-type: none"><li>• Sinus tachycardia</li></ul>
Atrium		<ul style="list-style-type: none"><li>• Ectopic atrial tachycardia (aHR usually &lt; 250 bpm) with (2:1) AV block</li></ul>
AV node	<ul style="list-style-type: none"><li>• PR prolongation &gt; 200 ms</li><li>• 2<sup>nd</sup> degree AV block, type Wenckebach</li><li>• 3<sup>rd</sup> degree AV block</li></ul>	<ul style="list-style-type: none"><li>• Junctional rhythm with narrow QRS at various HR (HR &lt; 40-60-120 bpm)</li></ul>
Ventricle		<ul style="list-style-type: none"><li>• PVC, bigeminy</li><li>• Ventricular tachycardias</li><li>• Bidirectional ventricular tachycardia</li><li>• Ventricular fibrillation</li></ul>

---

# Digoxin toxicity: Treatment

---

## Monitoring, supportive care

- Bed rest, avoid sympathetic stimulation
- Correct electrolyte abnormalities

Note: Hyperkalemia reflects the degree of digoxin toxicity

## Treatment of ventricular tachycardias

- Digitalis antibodies (Fab)
- Phenytoin (with a backup pacemaker)

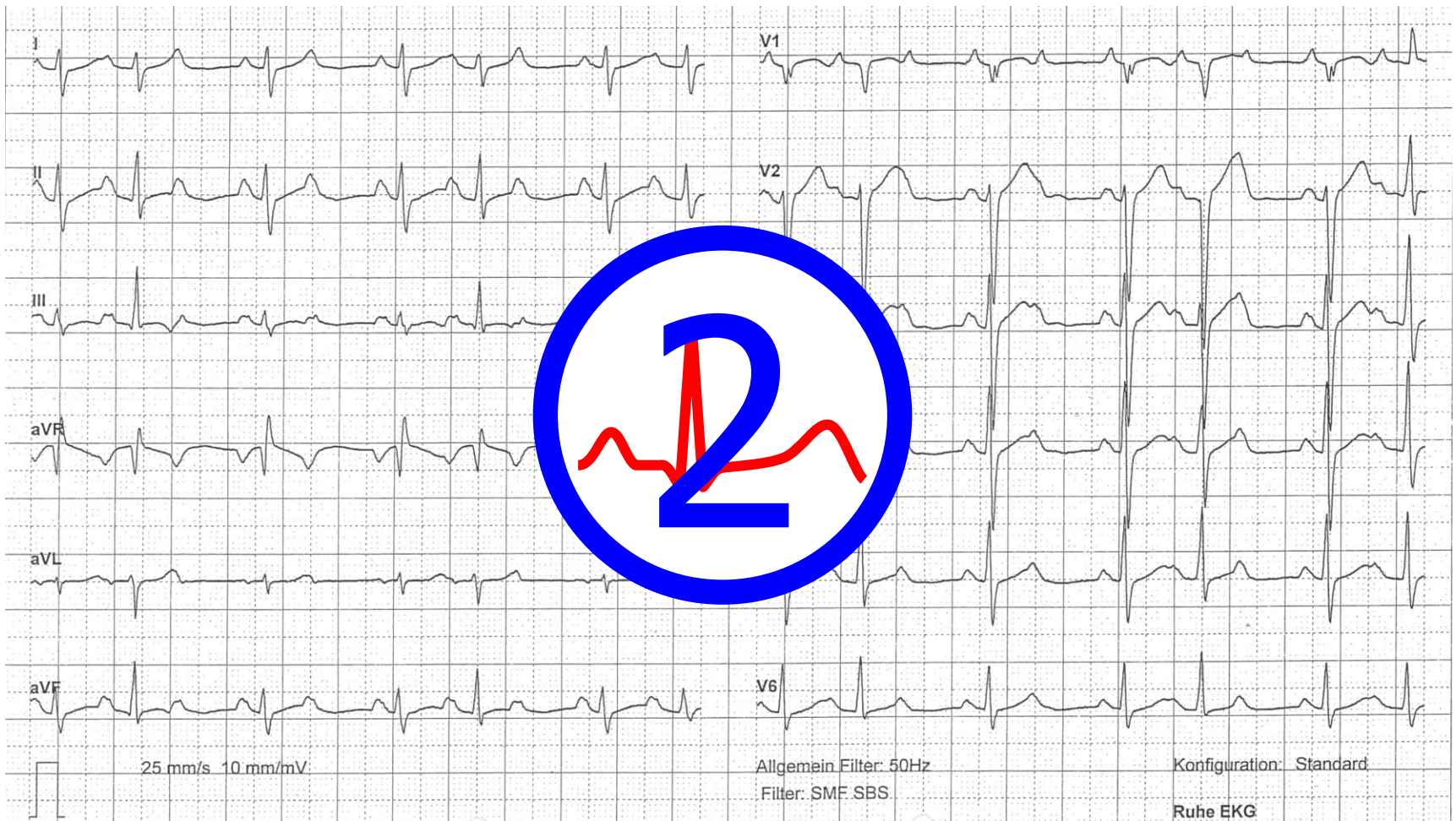
## Treatment of bradyarrhythmias


- Temporary ventricular pacing

## Avoid

- Rapid pacing (→ acceleration of tachycardias)
- Sudden cessation of pacing (→ asystole without escape rhythm)
- Carotid sinus massage (→ worsening of arrhythmias → VF)

# Complex arrhythmia treatment





# Case 4: History

37-year-old man with incessant supraventricular tachycardia

## Personal history:

1976 (1 y/o) Heart murmur. Heart catheterization (Kispi). Normal finding.  
1/12 Dyspnea, cough → different antibiotic therapies

## Current admission

2/12 Persistent tachycardia (HR 190 bpm) since at least 3 weeks.

## Clinical findings


115 kg, 185 cm, BMI 33.6 kg/m<sup>2</sup>, BP 105/75 mmHg, HR 190 bpm, SO<sub>2</sub> 93%.

## Laboratory values

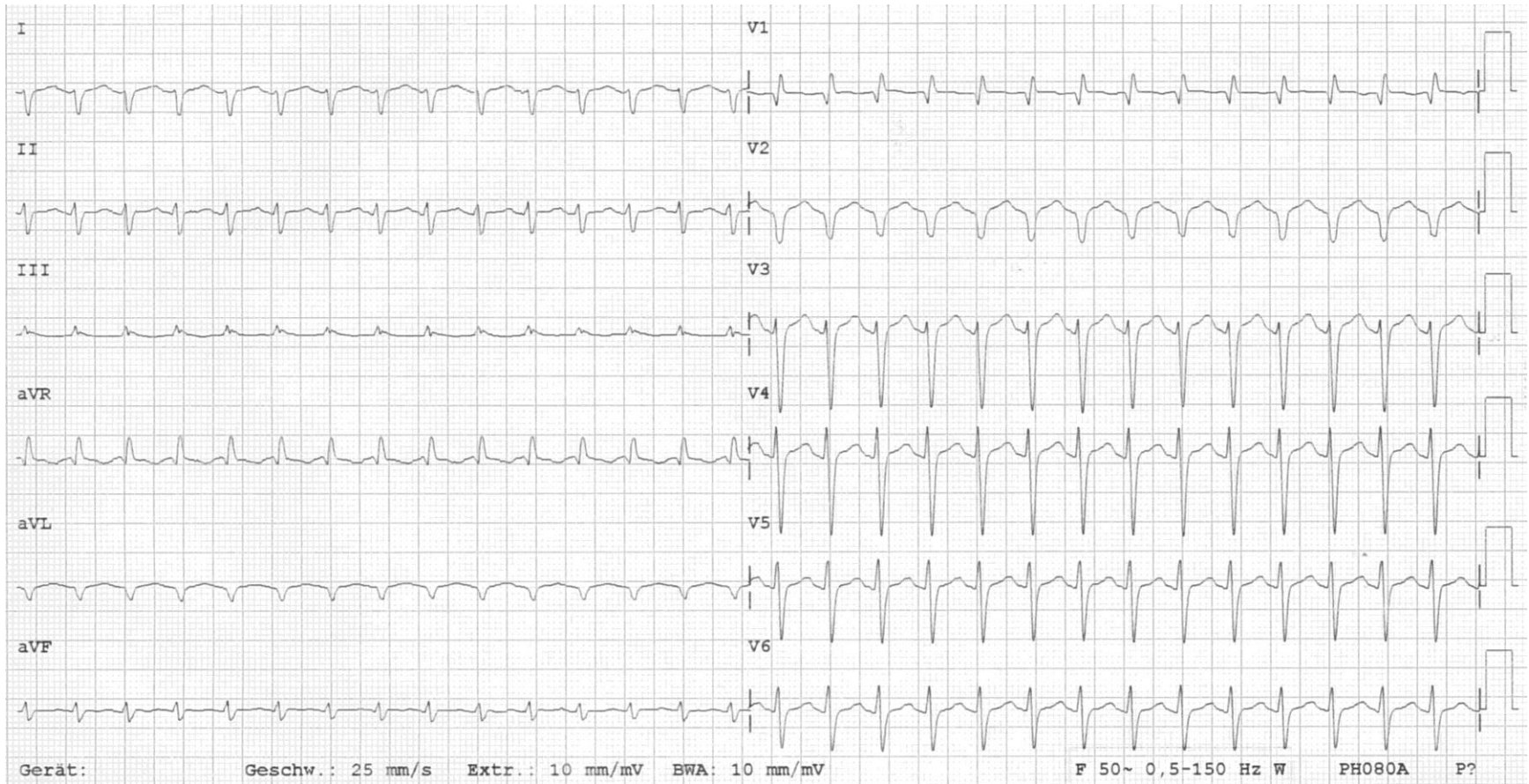
Lc 12.2 G/l, Hb 14.3 g/dl, Tc 100 G/l, INR 1.8, CRP 36 mg/l, Troponin: 14 ng/l. NT-proBNP 10'800 ng/l. ASAT and ALAT >3000 U/l.

**ECG:** next slide

**TTE:** LVEF 20%.



# Case 4: ECG

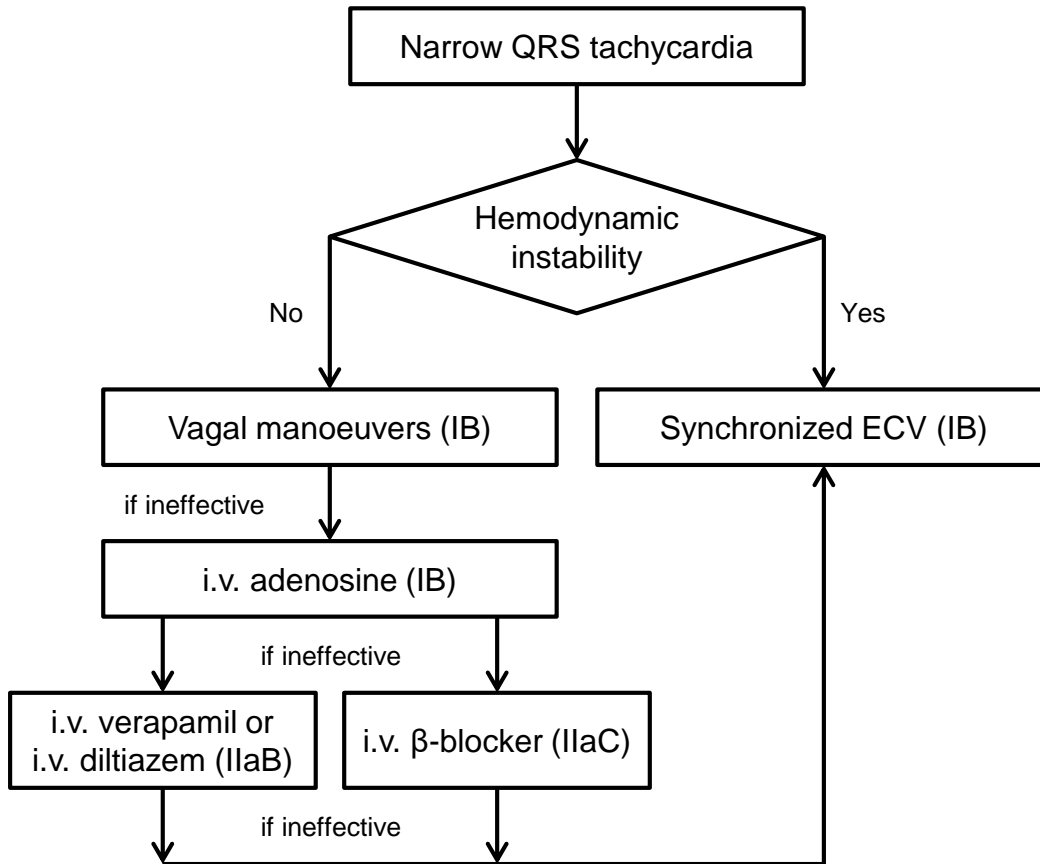


**ECG:** Narrow QRS tachycardia. HR 174 bpm, regular. Right axis.

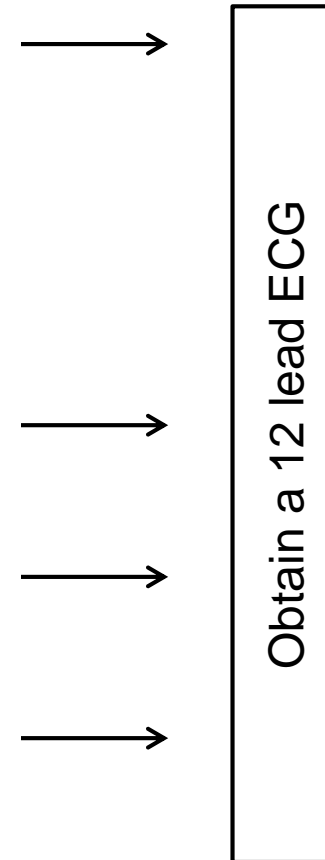



# Narrow QRS tachycardia: Acute therapy

## Acute therapy



## Differential diagnosis






# Case 4: Follow-up

## Acute therapy

Time	Therapy	HR
D1, +1h	Adenosine 12 mg i.v. Adenosine 18 mg i.v.	HR 190 bpm HR 190 bpm
D1, +4h	Electrical cardioversion (100 J) Electrical cardioversion (200 J)	HR 190 bpm HR 140 bpm
D1, +6h	Transfer to the ward	HR 190 bpm
D1, +7h	Amiodarone 300 mg i.v.	HR 174 bpm
D1, +8h	Adenosine 12 mg i.v.	HR 174 bpm
D1, +8h	Electrical cardioversion (200 J) Electrical cardioversion (200 J) Electrical cardioversion (200 J) Electrical cardioversion (150 J) Electrical cardioversion (150 J)	HR 174 bpm HR 174 bpm HR 174 bpm HR 174 bpm HR 174 bpm

→ Transfer to the ICU of the Triemli hospital

Zeit	Blutdruck	Puls	SO <sub>2</sub>	O <sub>2</sub>	Infusionen/Medikamente	Pflegebericht	Sz Skala
18:29	110/73	184	91%		30mg Propofol i/v	Temp. Otr: ax rec	
18:36	93/62	182	93%			Schock mit 200 J	
18:39	102/85	178	100%			Schock mit 200 J	
18:30	109/68	178	95%			Schock mit 200 J	
18:31	111/90	173	100%			Schock mit 150 J	
18:32	117/89	165	100%			Schock mit 150 J	
18:33	115/98	160	100%			ABG durch UHFV = ok. Pat schwitzt noch tief rest	
18:41	95/76	155	99%	Mask 6L			
18:54	94/78	150	98%			Pat schlief innerlich fiel	
18:58	90/76	175	98%			Pat wird langsam wach	
19:03	95/64	184	94%				

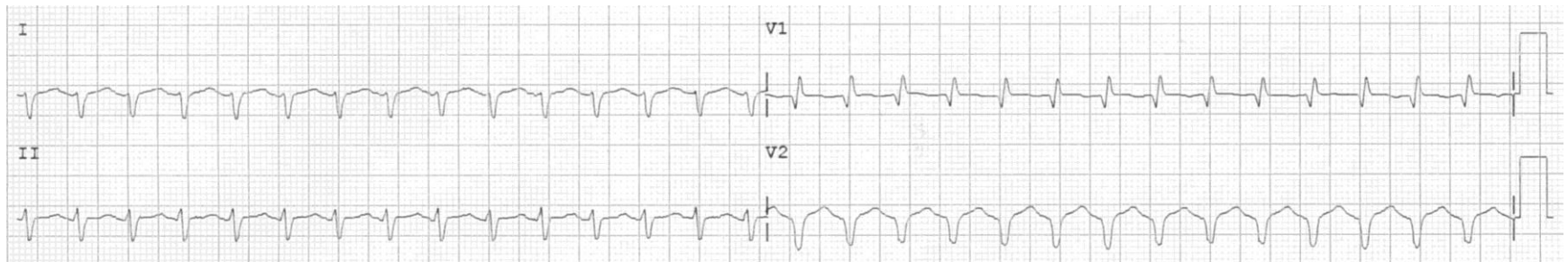



# Case 4: Question

37-year-old man with incessant supraventricular tachycardia

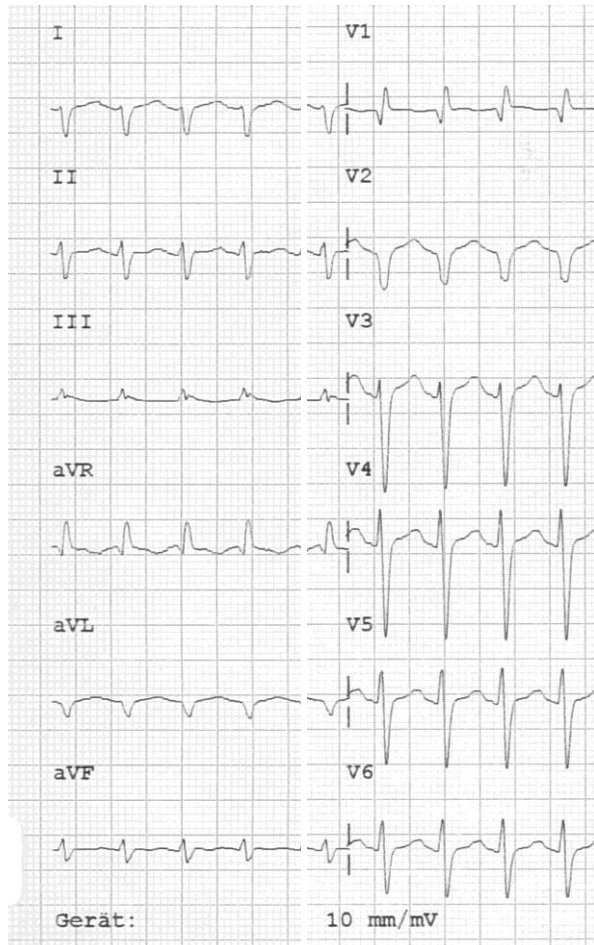
How would you treat this patient? (more than one correct answer)

- (A) Amiodarone i.v. → repeat electrical cardioversion
- (B)  $\beta$ -blocker + verapamil → repeat adenosine
- (C) Temporary pacemaker → AV node ablation
- (D) Electrophysiological study → SVT catheter ablation
- (E) ECMO or assist device

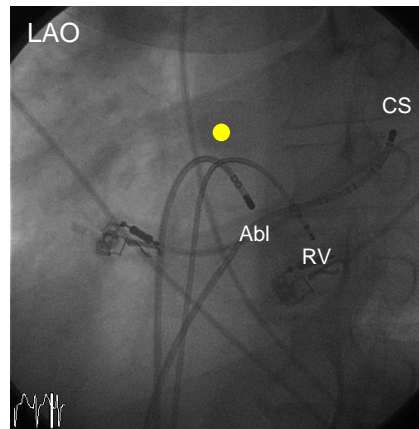
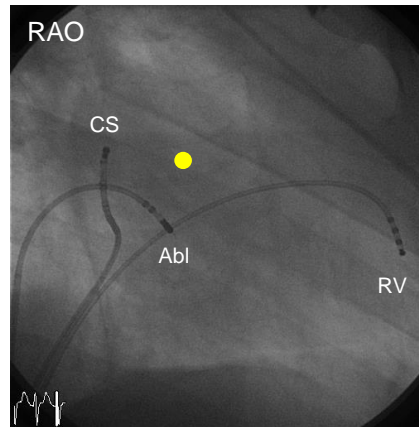




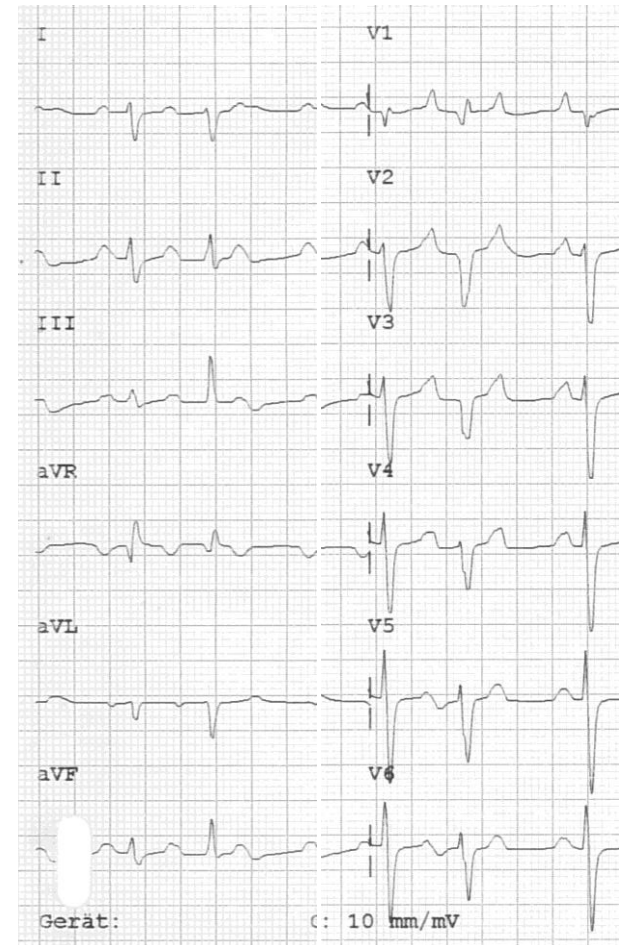
# Case 4: EPS (1)




**ECG:** AVNRT. HR 174 bpm.



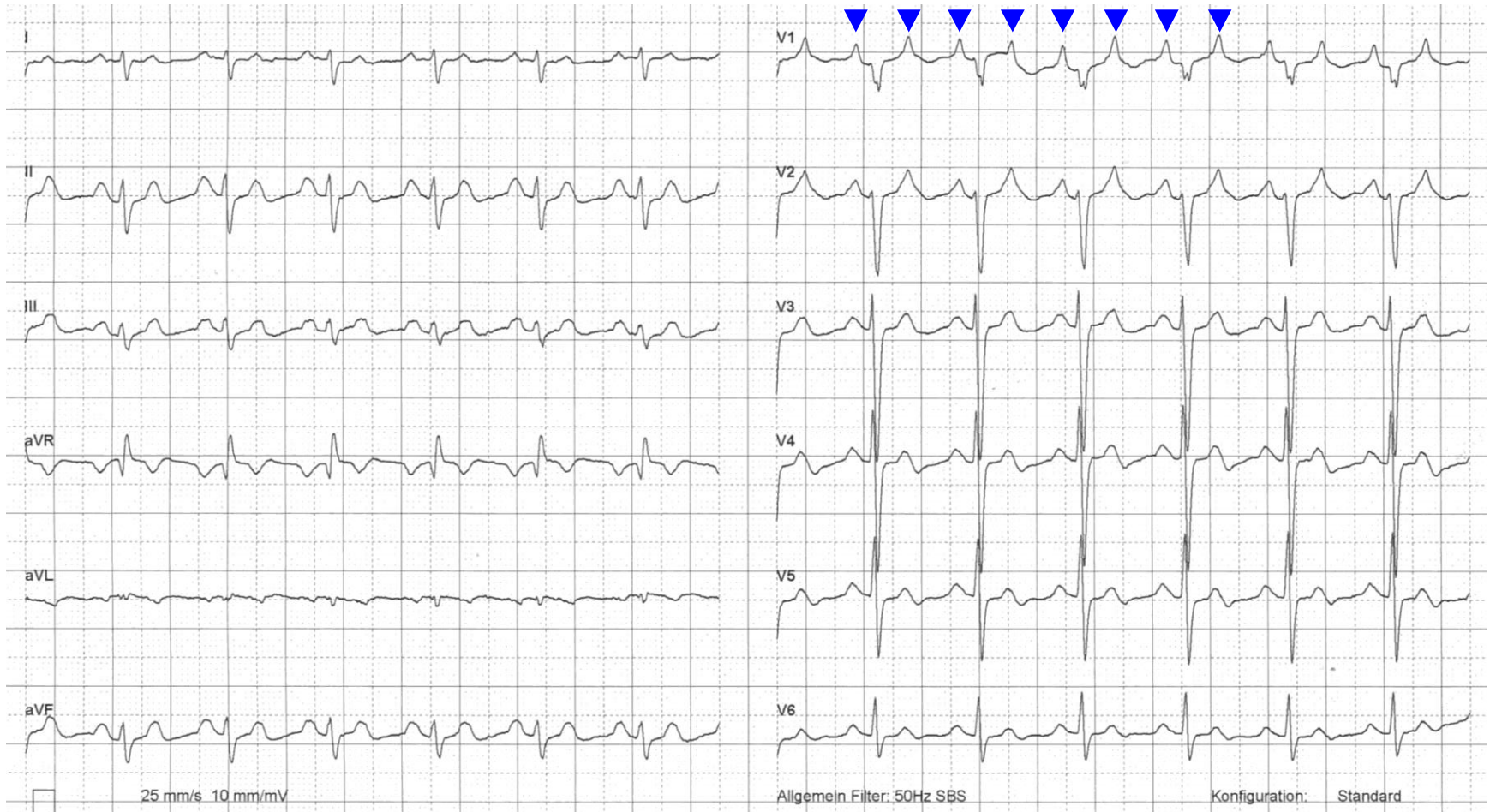
**EPS:** Slow pathway ablation




**ECG:** SR, changing AV conduction?



# Case 4: ECG



**ECG:** Atrial tachycardia (aCL 360 ms) with 2:1 AV conduction (vHR 84 bpm). Right axis.

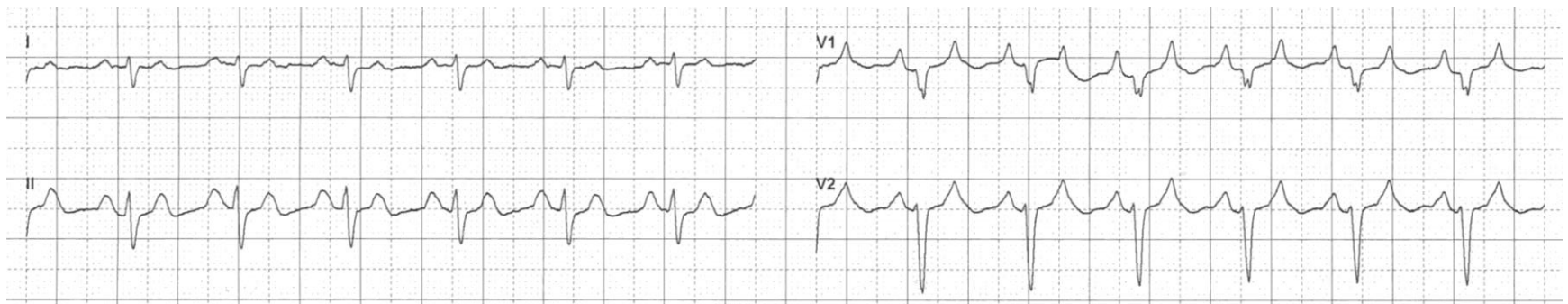



# Case 4: Question

37-year-old man with incessant atrial tachycardia and heart failure

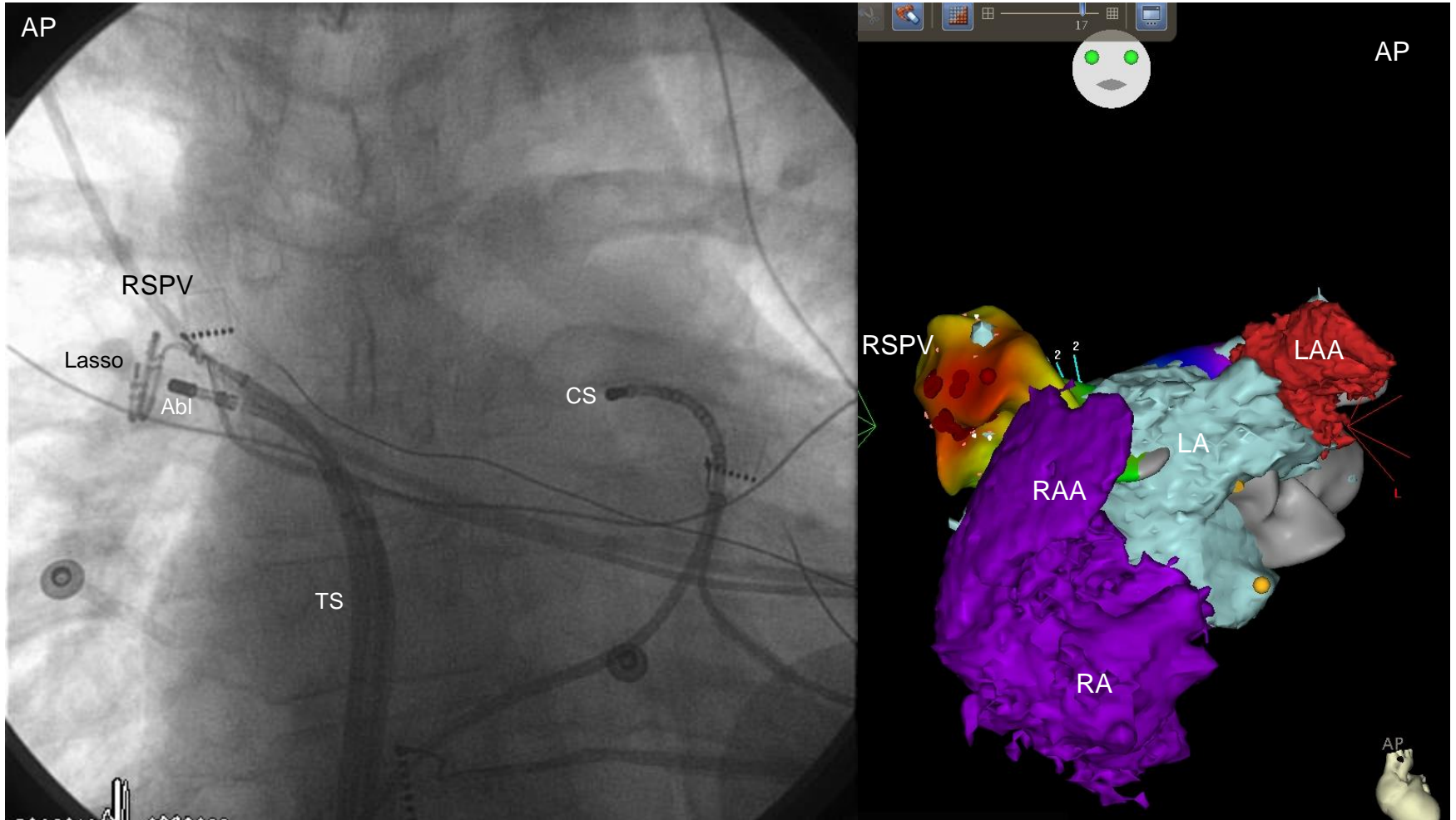
How would you treat this patient? (more than one correct answer)

- (A) Heart failure therapy (ACE inhibitor,  $\beta$ -blocker, spironolactone, ...)
- (B) Flecainide
- (C) Amiodarone
- (D) Electrophysiological study  $\rightarrow$  SVT catheter ablation
- (E) Pace & ablate (permanent pacemaker  $\rightarrow$  AV node ablation)






# Case 4: EPS (2)



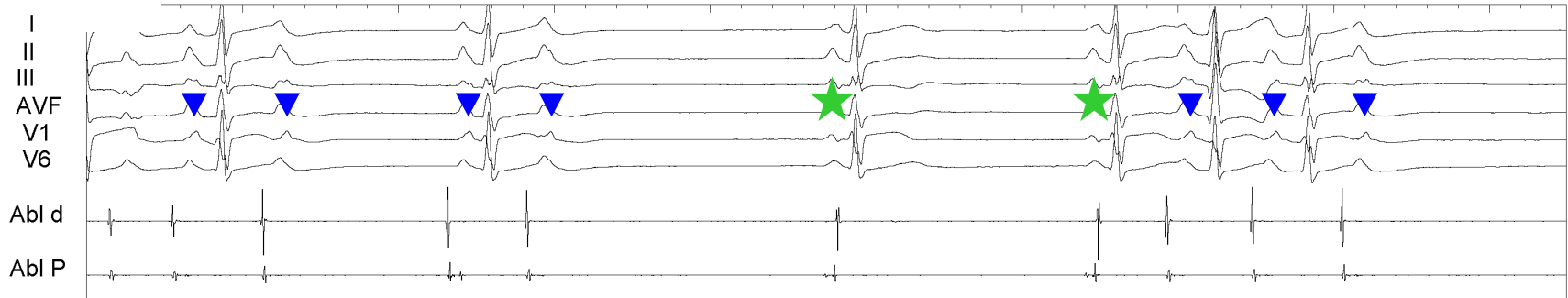
**EPS:** Mapping and ablation of the focus in the RSPV (fluoroscopy and 3D mapping system).



# Case 4: Follow-up

## Diagnosis

1. Incessant AV nodal reentry tachycardia (AVNRT)  
→ slow pathway ablation (day 2)
2. Incessant focal atrial tachycardia  
→ ablation of the focus in the RSPV (+5 months)
3. Tachycardia induced cardiomyopathy with systolic heart failure



**EPS:** Termination of the focal atrial tachycardia (FAT, arrow heads) with conversion to SR (asterisks).

**Therapy:** pharmacological heart failure therapy


**Follow-up:** 6 years later: stable SR, normal LVEF



# SVT: Chronic therapy

Dx	IC	II	Sotalol	Amio	IV	Iva	Other	Ablation
<b>SR tc</b>	-	IIaC	-	-	IIbC	IIaB	IC*	IIaC
Efficacy	-	-	-	-	-	-	-	-
<b>FAT</b>	IIaC	IIaC	-	IIbC	IIaC	IIbC	-	IB
Efficacy	-	-	-	-	-	-	-	85%
<b>AVNRT</b>	-	IIaB	-	-	IIaB	-	-	IB
Efficacy	-	25%	-	-	25%	-	-	97%
<b>AVRT</b>	IIbB§	IIaB°	-	-	IIaB°	-	-	IB
Efficacy	-	-	-	-	-	-	-	92%
<b>AFL</b>	-	IIaC	-	IIbC	IIaC	-	-	IA/B
Efficacy	-	-	-	-	-	-	-	95% / 80%
<b>AF</b>	IA†	-	IA†	IA†	-	-	IA#†	IIaB / IA
Efficacy	33%	20%	33%	65%	-	-	33%	65-85%

Dx denotes diagnosis, Sotalol sotalol, Amio amiodarone, Iva ivabradine, AVNRT AV node reentry tachycardia, AVRT AV reentrant tachycardia, FAT focal atrial tachycardia, AF atrial fibrillation, rhythm control. \* Treatment of underlying disorder. ° only for orthodromic AVRT, § for anti-/orthodromic AVRT. † selected indication depending on the underlying heart disease. # Dronedaron.



---

# Case 5: History

---

51-year-old patient with bicuspid aortic valve and an aneurysm of the ascending aorta


## Admission for surgery

Implantation of a composite graft with mechanical prosthetic aortic valve  
Cardiopulmonary bypass: Arterial to the aortic arch, venous to the RA  
Uneventful. Spontaneous recovery of SR at the end of the operation

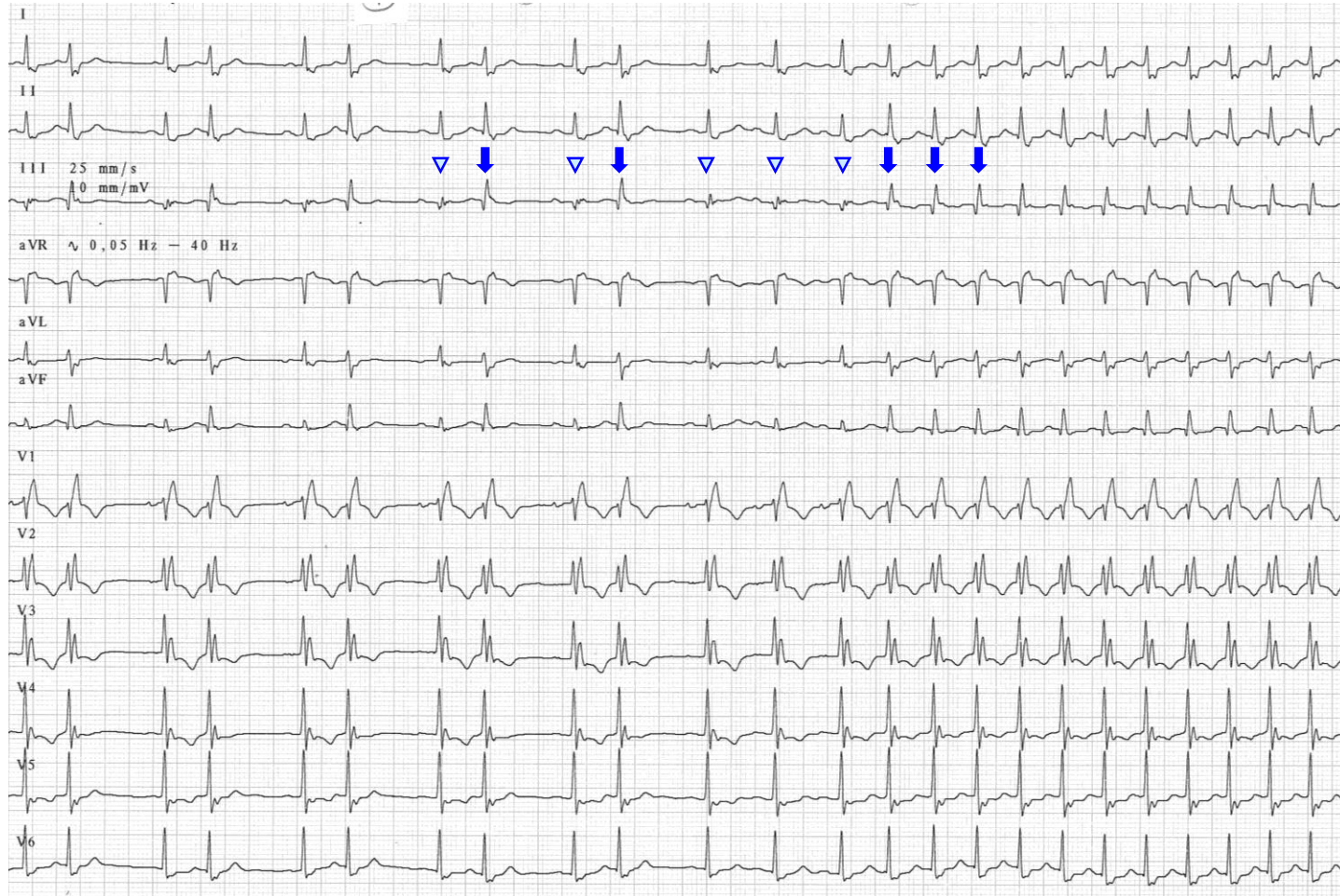## In hospital follow-up

Day 1: Transfer ICU → ward  
ECG: SR, complete RBBB


Day 11: Repetitive (non-)sustained episodes of wide QRS tachycardias  
Therapy: VKA, aspirin, ACE-inhibitor, no AAD



# Case 5: ECG



**ECG:** SR with RBBB and bigeminy. Start of a regular tachycardia with wide QRS complexes (CL 440ms). Morphology identical to the bigeminy and similar to the QRS complex in SR.

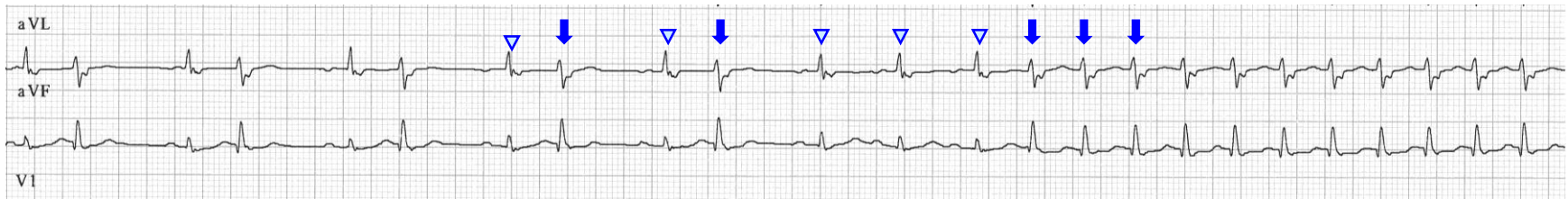



# Case 5: Question

51-year-old patient post cardiac surgery (SJM 27 mm composite graft)

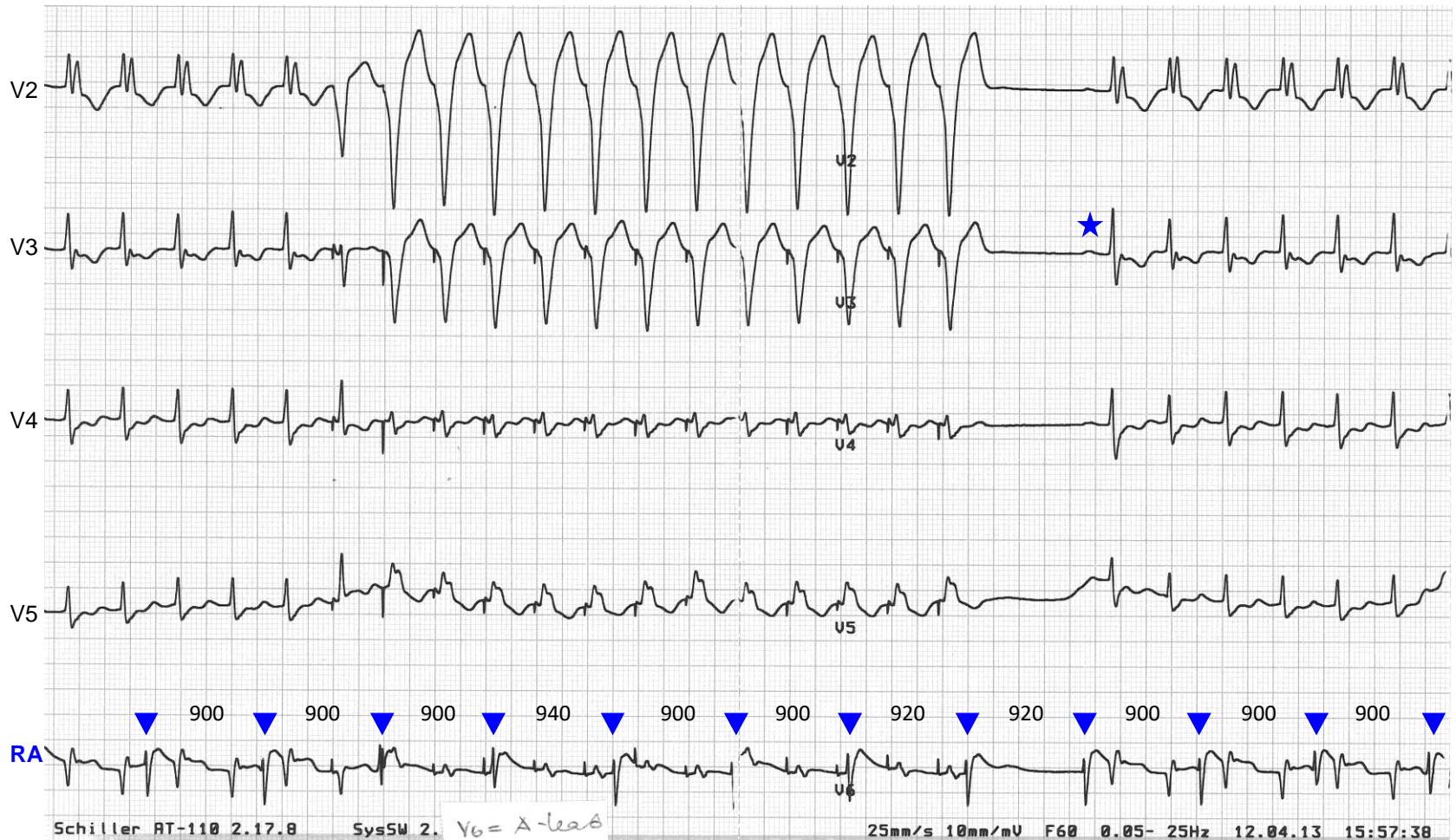
How would you treat this patient? (more than one correct answer)

- (A) Dx: SVT → Th: Adenosine →  $\beta$ -blocker
- (B) Dx: VT → Th: Amiodarone
- (C) Dx? → Electrophysiological study
- (D) Dx: VT → ICD
- (E) Dx: VT → Catheter ablation






# Case 5: Non-invasive EPS



**ECG and atrial EGM recording on V6:** Ventricular overdrive pacing (CL 400ms) with termination and immediate reinitiation of the ventricular tachycardia with 2:1 VA conduction. **Diagnosis:** Ventricular tachycardia



---

# Case 5: Diagnosis and therapy

---

## Diagnosis

Ventricular tachycardia, DD:


- Non LBBB form of Bundle branch reentry
- Septal accelerated idioventricular rhythm (AIVR) type tachycardia
- Junctional ectopic tachycardia
- His reentry

## Therapy

Amiodarone

## Follow-up

Successful suppression of the arrhythmia



# Case 6: History

57-year-old patient with subacute STEMI

## Personal history

Arterial hypertension

## Current admission

Atypical back pain for 3 days followed by stress intolerance 2 weeks ago.

Acute dyspnea and chest pain → ER of another hospital → transfer to Triemli.

## Clinical findings

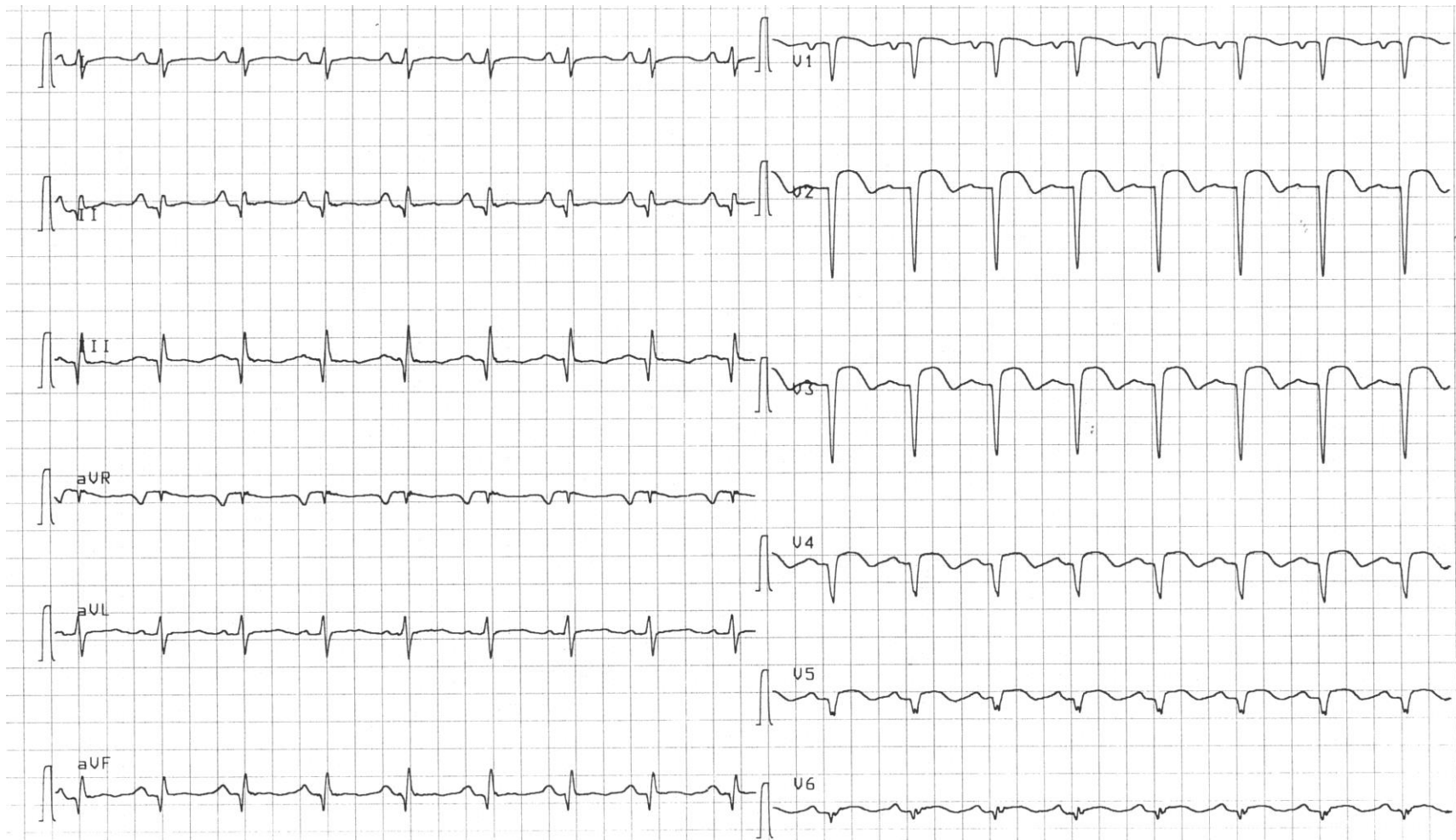
**ECG** (next slide), **TTE**: LVEF 40%, anterior aneurysm

**Laboratory values:** Lc 12.2 G/l, Hb 13.7 g/dl, Tc 125 G/l, CRP 4.7 mg/l, Na 138 mmol/l, K 4.13 mmol/l, Crea 94  $\mu$ mol/l, CK 96 IU/l, Trop T 925 ng/l.

## Diagnosis

Subacute anterior STEMI with pulmonary edema

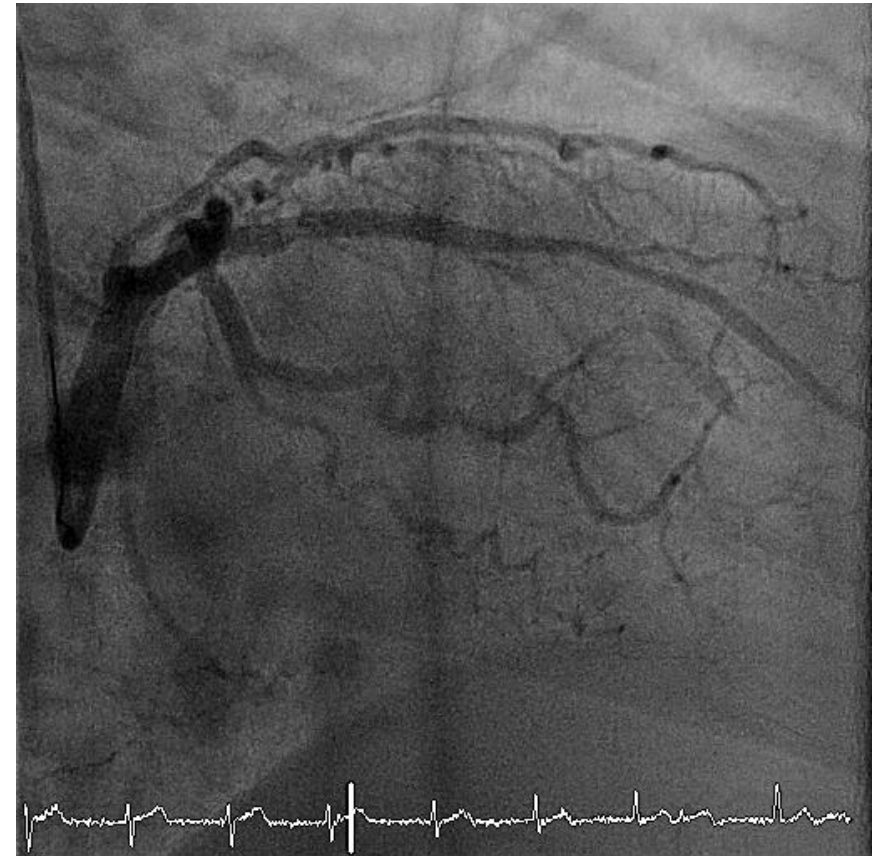
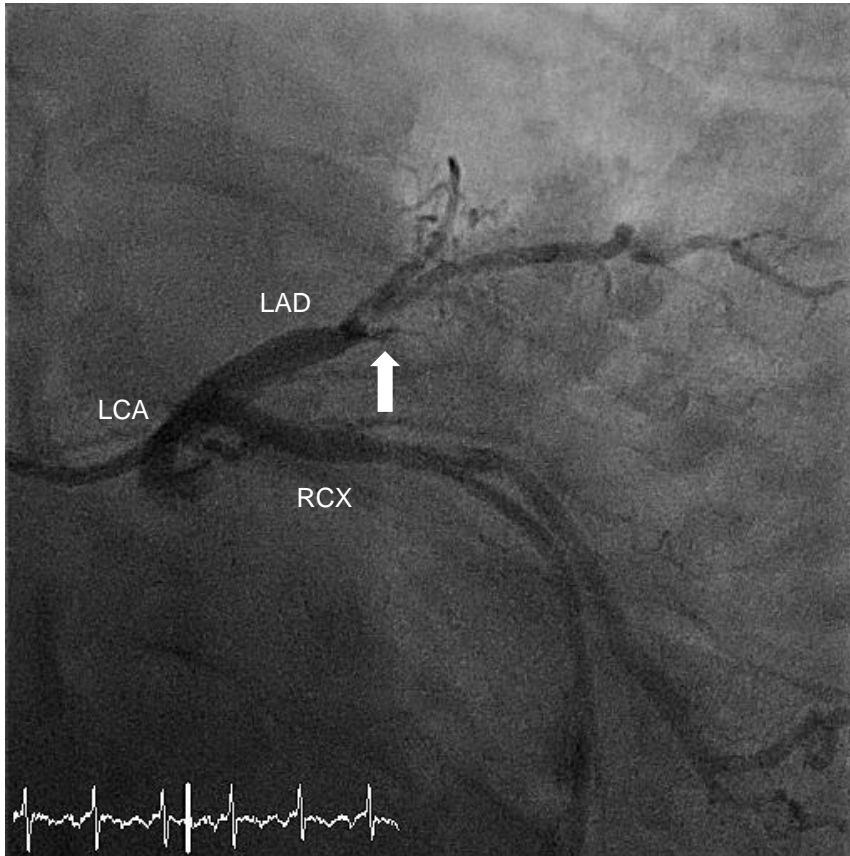
# Case 6: ECG



**ECG:** SR. HR 100 bpm. Q in II, III, aVF, and V1-V6. ST-elevation in V1-V6.



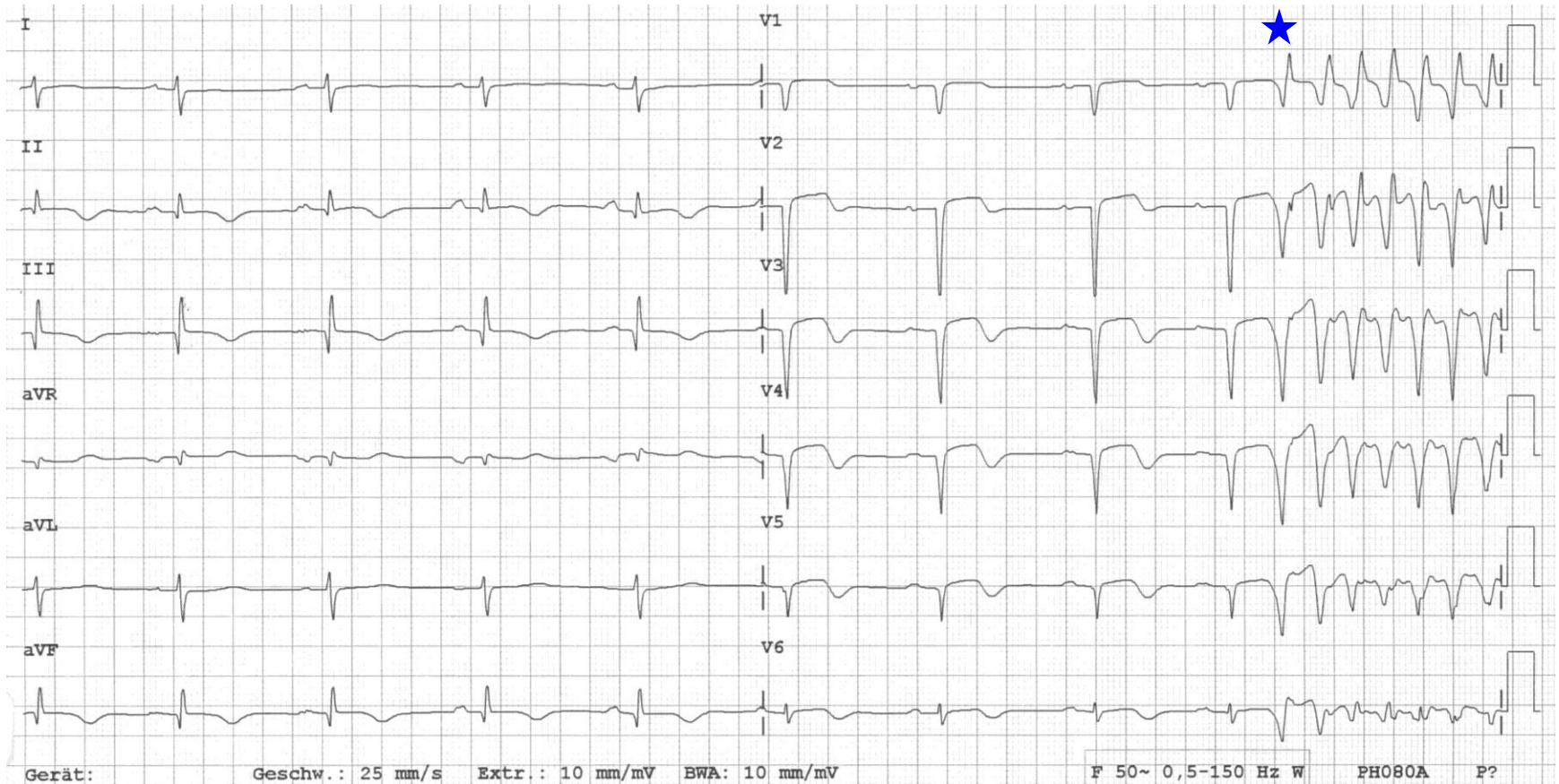
# Case 6: Revascularization



**Coronary angiography:** Occlusion of the proximal LAD. LVEF 35%. PCI with 2 stents.

# Case 6: ECG

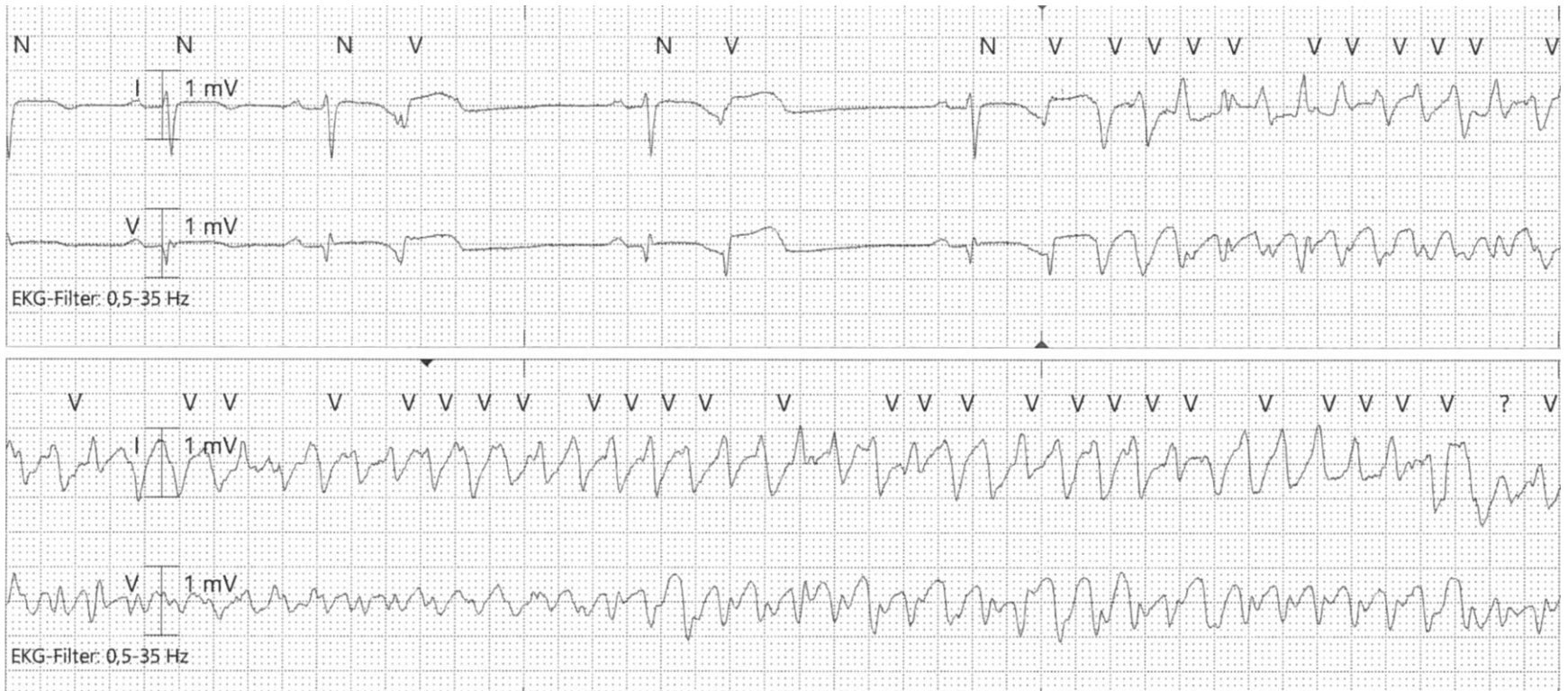
**Follow-up:** Repetitive (non-)sustained VT and VF → CPR and DC shocks



**ECG:** SR. HR 60 bpm. Q in I and persistent ST-elevation in V1-V5. Negative T in II, III, aVF, and V1-V6. Onset fast VT.

# Case 6: ECG

**Follow-up:** Repetitive (non-)sustained VT and VF → CPR.



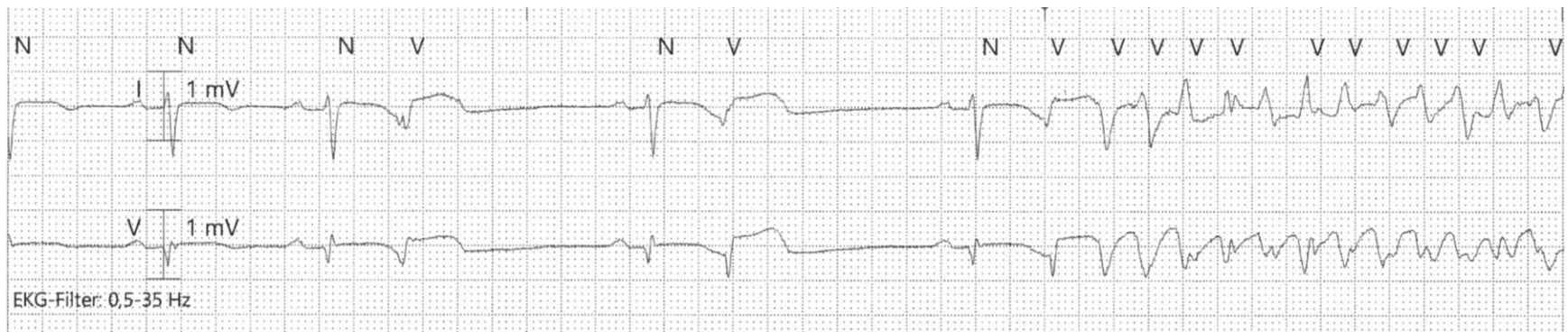
**ECG:** SR with PVCs (long-short-long) initiating VF.

# Case 6: Question

57-year-old patient with subacute STEMI and ventricular storm

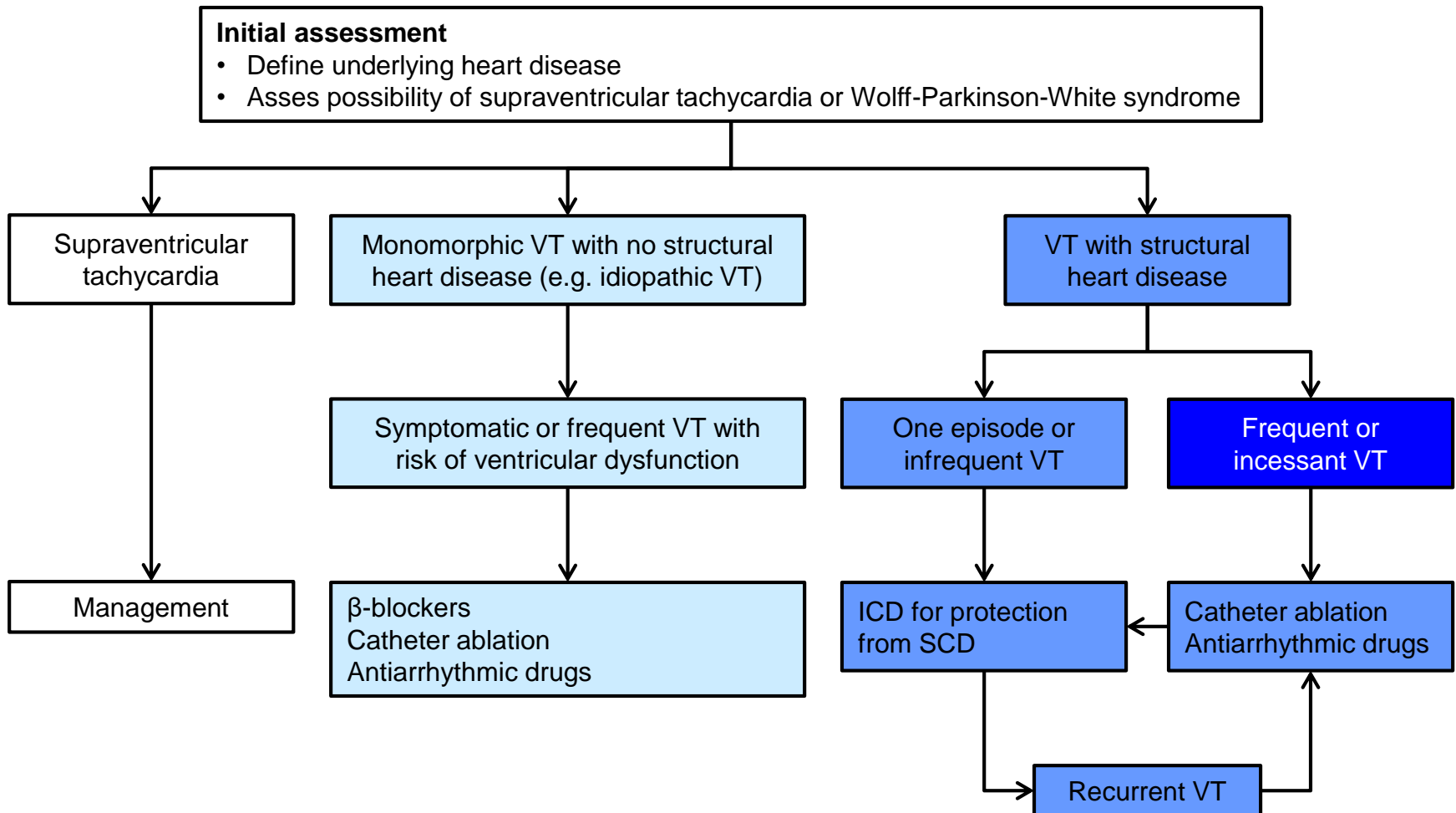
How would you treat this patient? (more than one correct answer)

- (A)  $\beta$ -blocker
- (B) Amiodarone
- (C) Lidocaine
- (D) ICD
- (E) VT ablation



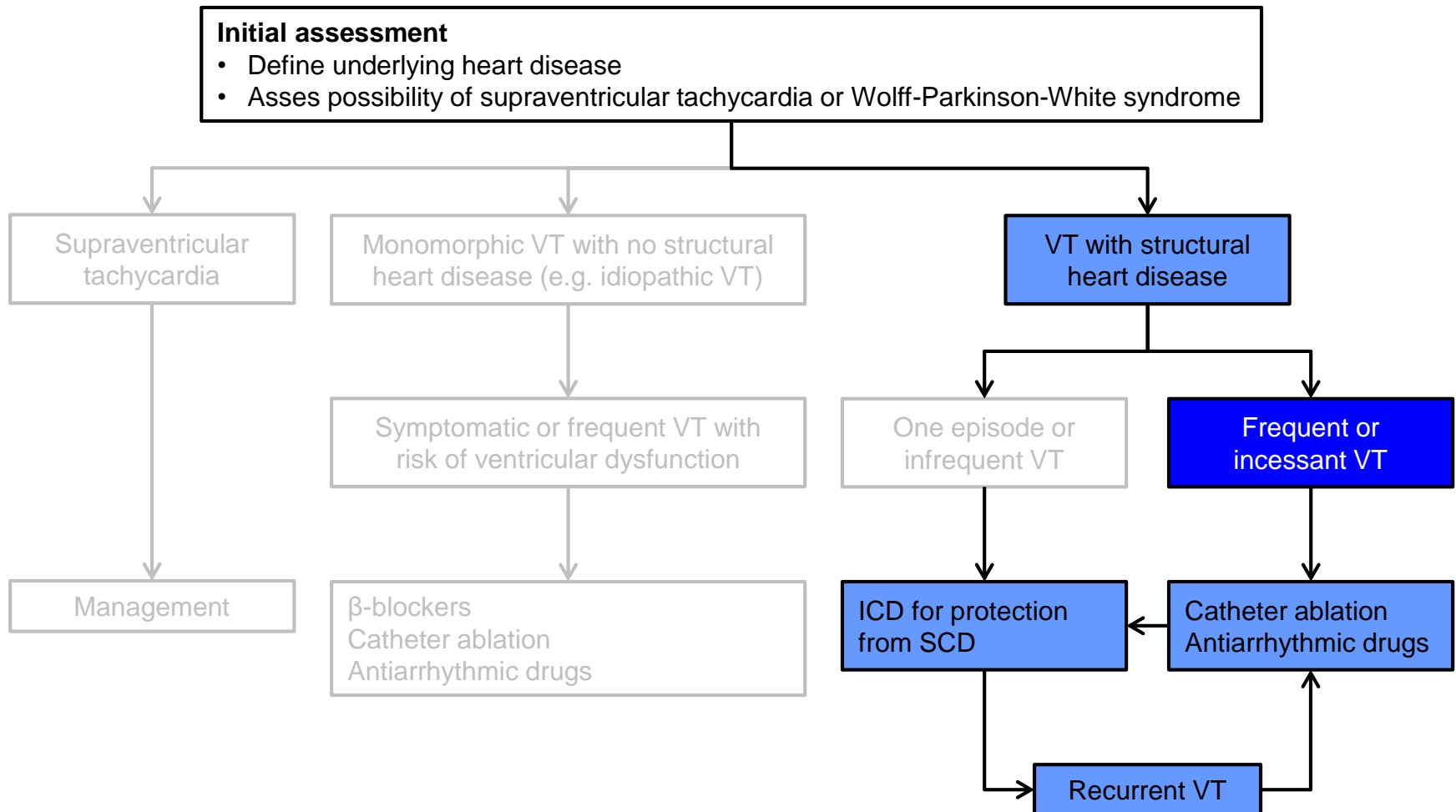
# Management

## After sustained wide QRS tachycardia



# Case 6: Management

## After sustained wide QRS tachycardia



---

# Therapies of VT in structural heart disease

---

## 1. Acute treatment

Cardioversion/Defibrillation, BLS and ACLS

## 2. Treatment of underlying heart disease

## 3. Supportive measurements

Electrolytes, sedation, and others

## 4. Pharmacotherapy

Antiarrhythmic drugs

{ Class IB: lidocaine, mexiletine  
Class II:  $\beta$ -blocker  
Class III: sotalol, amiodarone

## 5. Device therapy

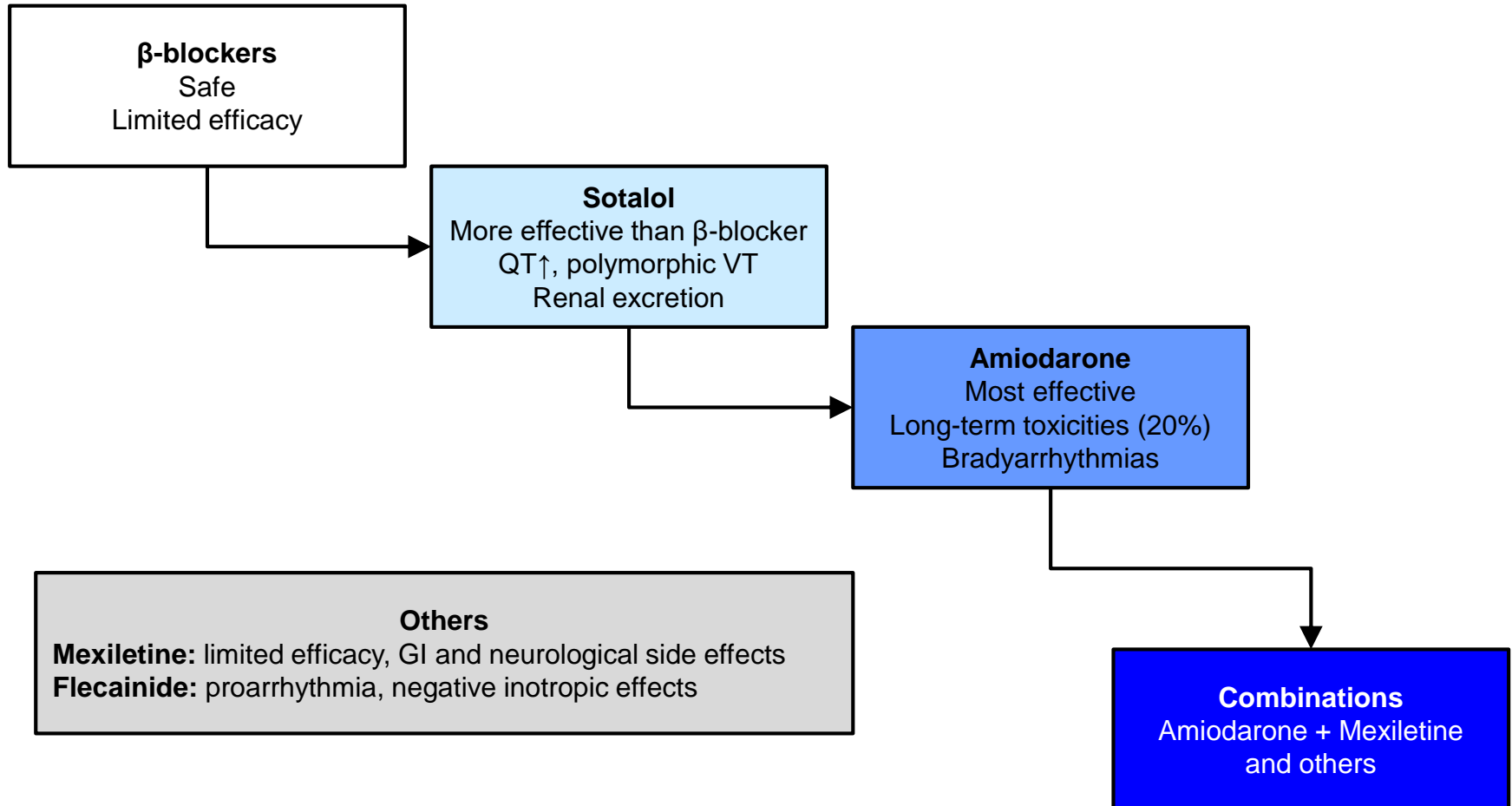
ICD, CRT-D, S-ICD, WCD

## 6. Interventional therapy


Catheter ablation, anti-arrhythmic surgery

# Antiarrhythmic drugs: Summary

## Antiarrhythmic drugs for ventricular arrhythmias







# Case 6: Therapy

## Management of incessant VT/VF

Coronary angiography: all arteries and stents open

Sedation → general anesthesia

HF therapy: ACEI,  $\beta$ -blocker, spironolactone

AAD: Amiodarone (bolus, i.v.) →

Lidocaine (1.0-1.5 mg/kg, repeat 0.5-0.75 mg/kg bolus, max. 3 mg/kg

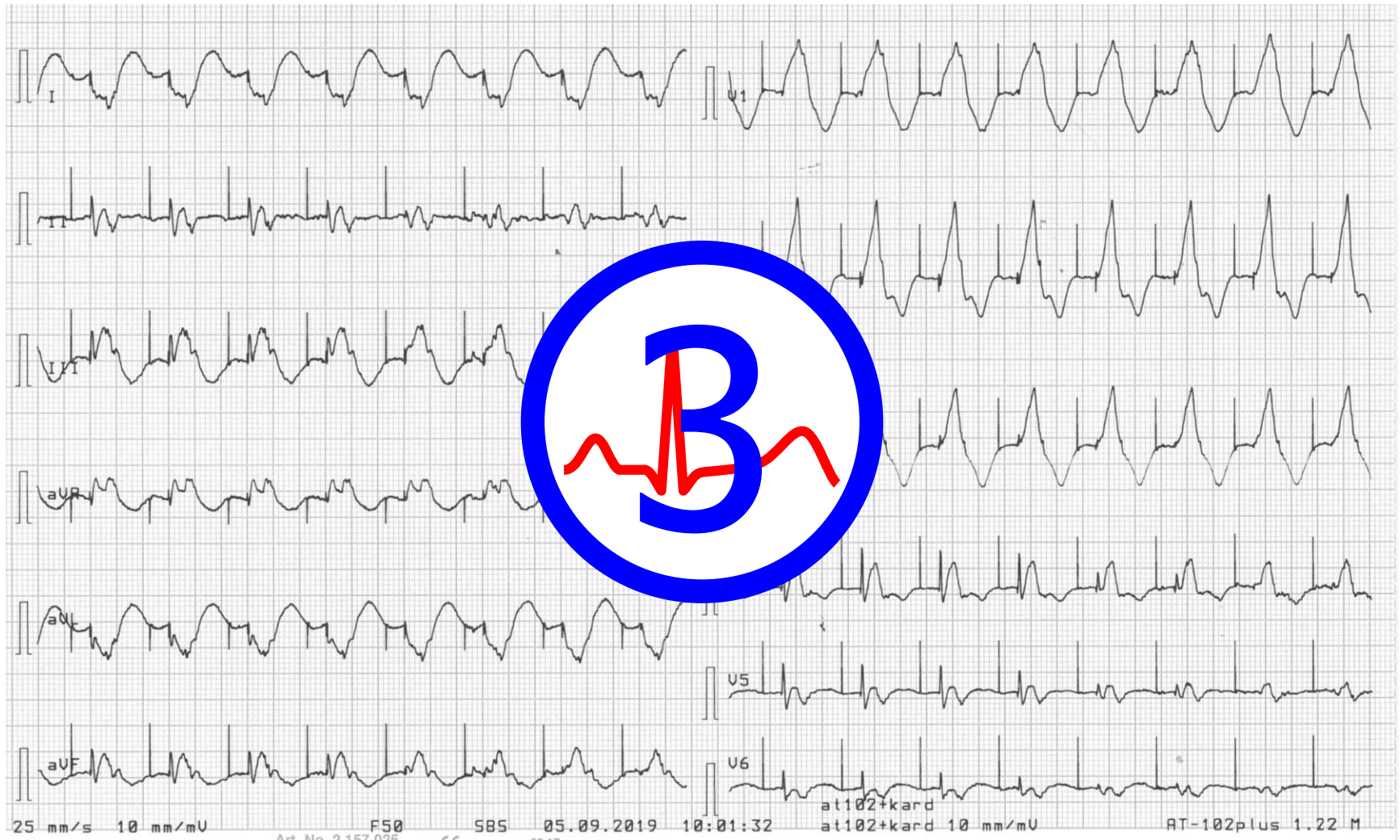
Infusion 1-4 mg/min)

Temporary RV pacemaker: avoid bradycardia induced PVC (short-long-short)

## Follow-up

Persistent refractory shock → transfer to the University hospital

# Complex device situations



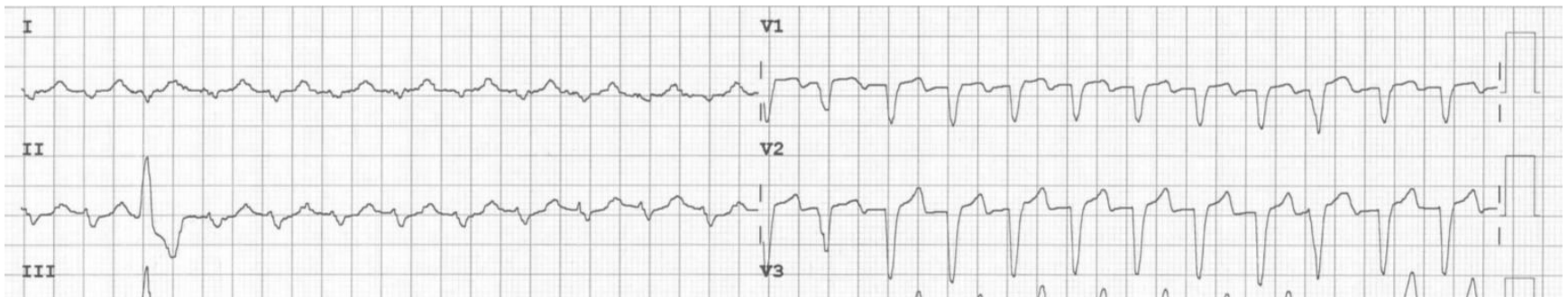


# Case 7: History


60-year-old patient with DCM and severe tricuspid regurgitation

## Cardiac history

- 2008 Dilative cardiomyopathy – OMT, dual chamber ICD (I° prevention)
- 2013 Lead fracture – Explantation and reimplantation of an ICD
- 2018 Progressive, severe tricuspid regurgitation (flail leaflet)
- 2019 Tricuspid valve reconstruction and explantation of the RV lead  
Postoperative repetitive sustained VT



**ECG:** Regular wide QRS tachycardia (HR 144 bpm).

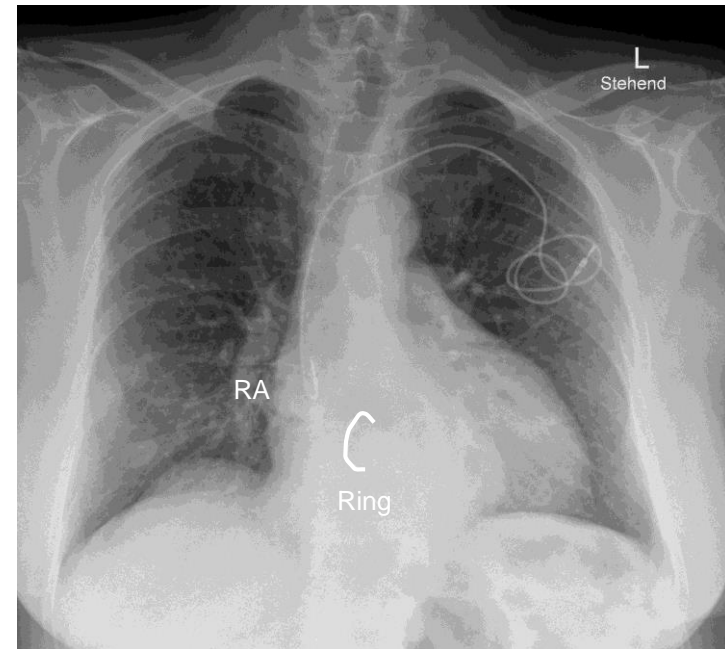
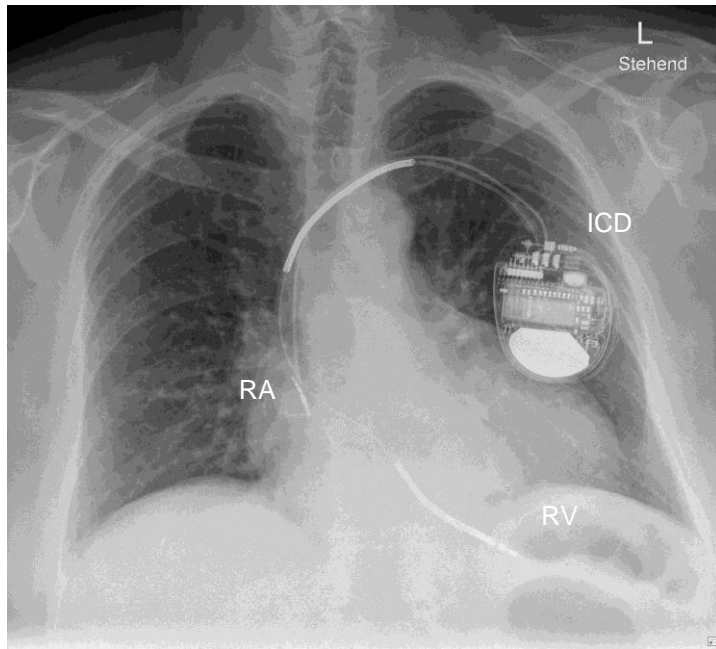


# Case 7: Question


60-year-old patient with DCM and severe tricuspid regurgitation

How would you treat this patient? (more than one correct answer)

- (A)  $\beta$ -blocker                      (B) Amiodarone                      (C) VT ablation  
(D) Transvenous ICD                (E) Subcutaneous S-ICD

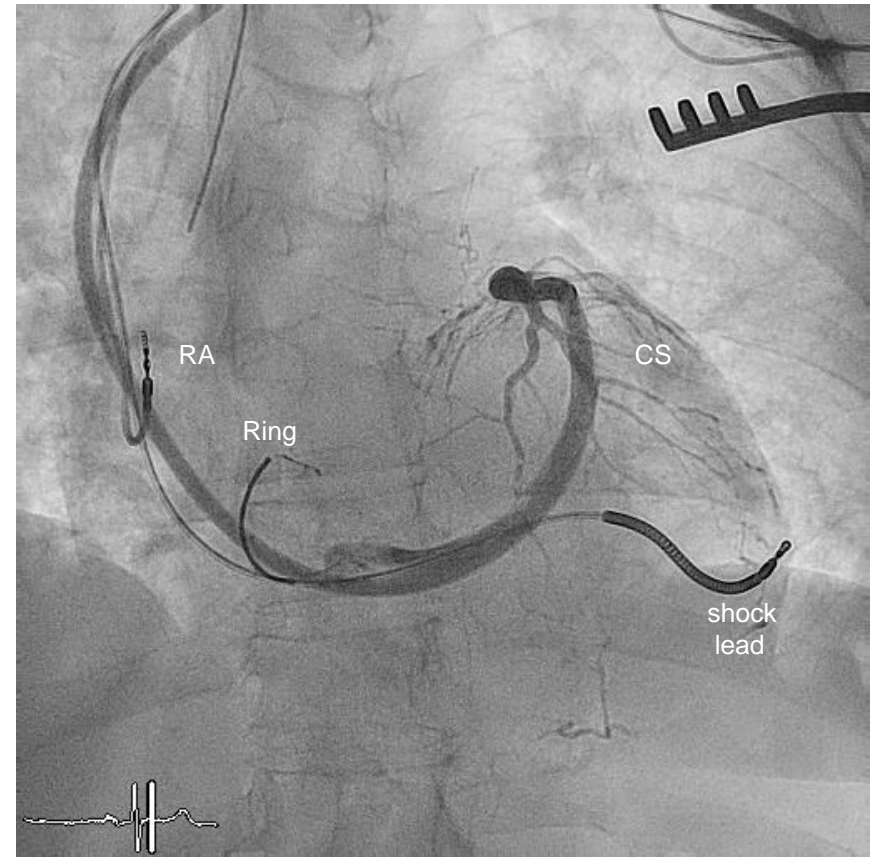
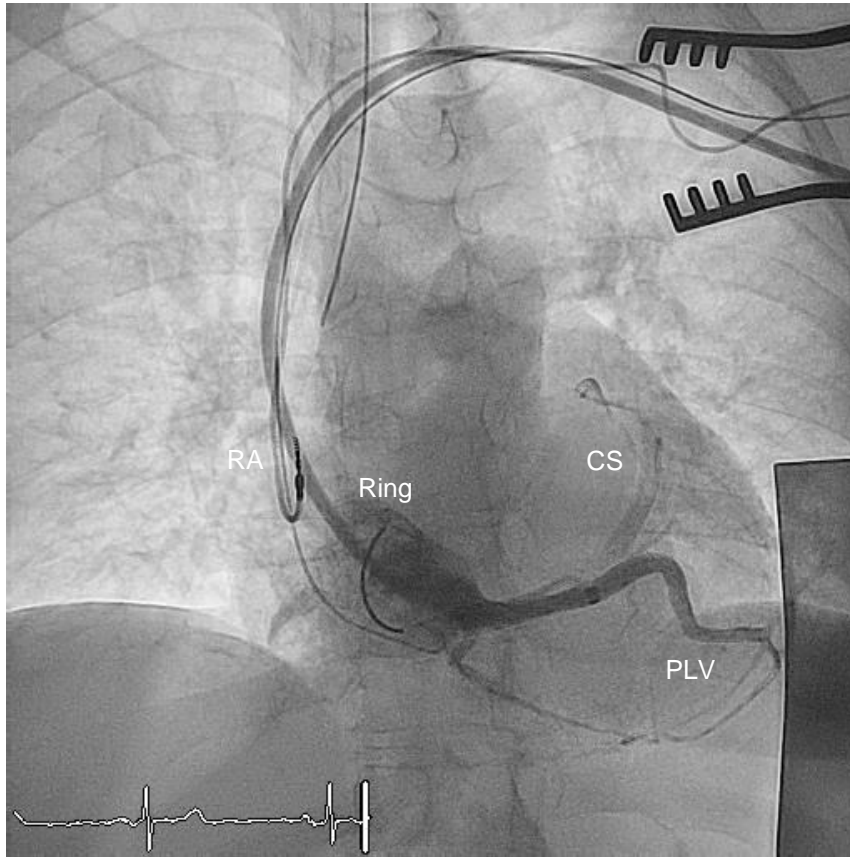


**Chest X-ray:** Before and after tricuspid valve reconstruction and extraction of the dual coil RV shock lead.




# Case 7: Therapy

## Implantation of a transvenous ICD with RV/shock lead in the CS

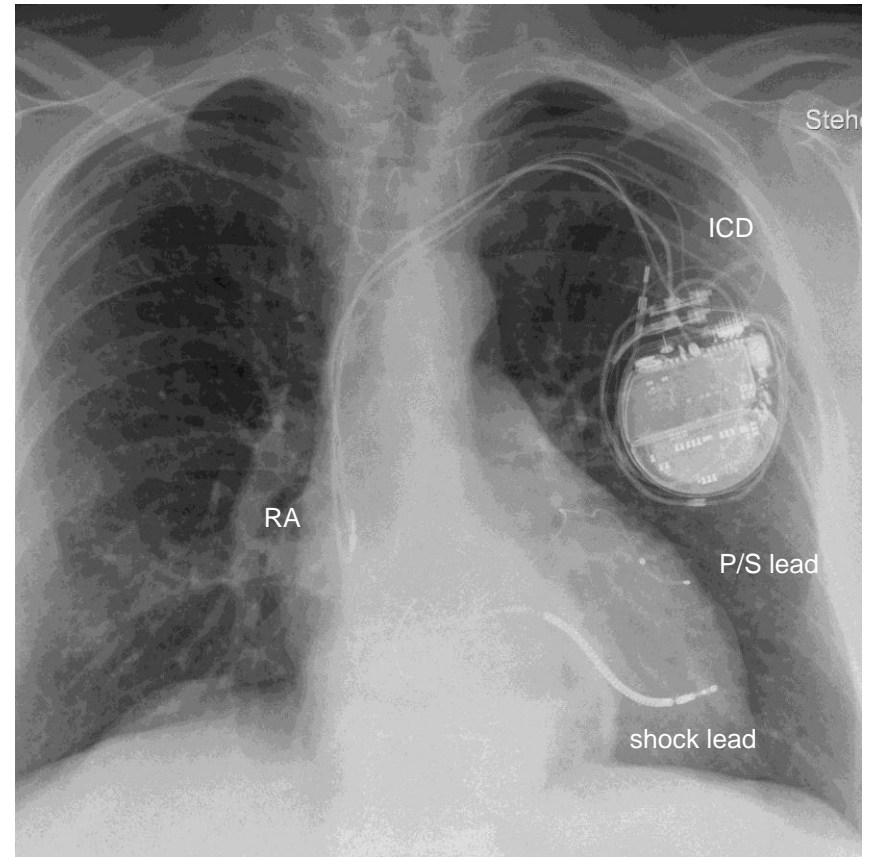
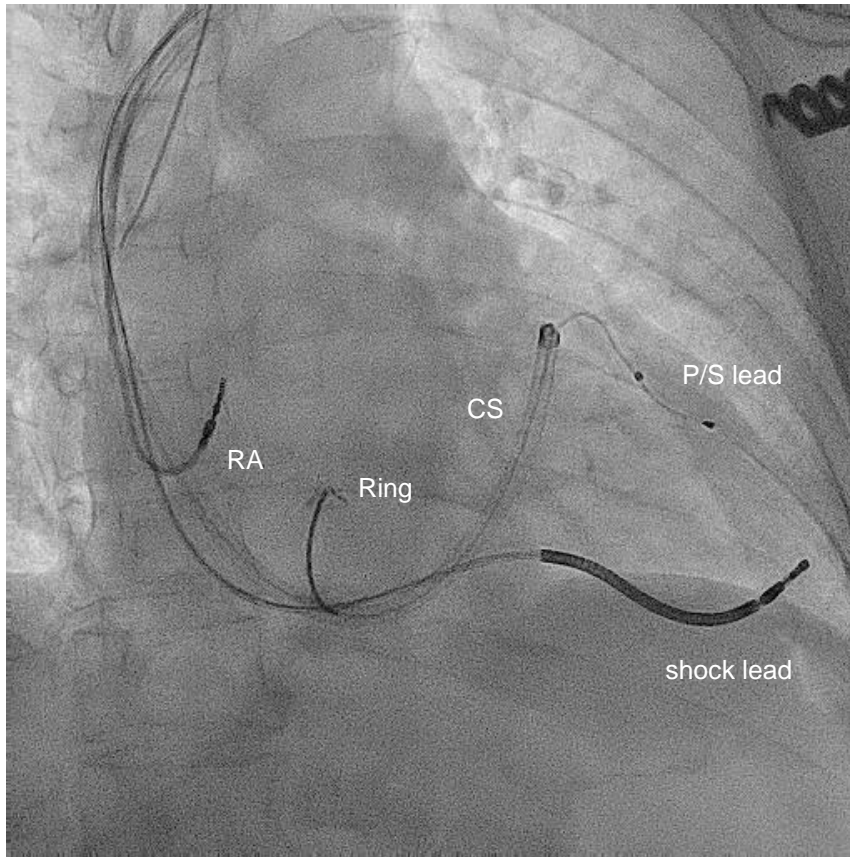


**CS venography:** Implantation of the RV shock lead in the posterolateral branch of the CS.



# Case 7: Therapy

## Implantation of a transvenous ICD with RV/shock lead in the CS



**Implantation:** Pace/Sense lead in an anterolateral side branch of the CS. Final chest X-ray.

---

# Summary

---

## (1) Complex electrocardiograms

- Physiology of the conduction system and the ECG
- Different pacing algorithms in modern PM and ICD
- Pharmacology of antiarrhythmic drugs

## (2) Complex arrhythmia treatment

- Catheter ablation, the treatment of choice for (most) SVT
- Additional tools for rhythm diagnosis (e.g. CIED)
- Management of ventricular storm

## (3) Complex device situations

